




★  
THE PEOPLE'S REPUBLIC  
OF VENICE

Notte Dome  
FOOTBALL





# The Year in Review

## 2005-2006

Paul K. Shitabata, M.D.

Dermatopathologist

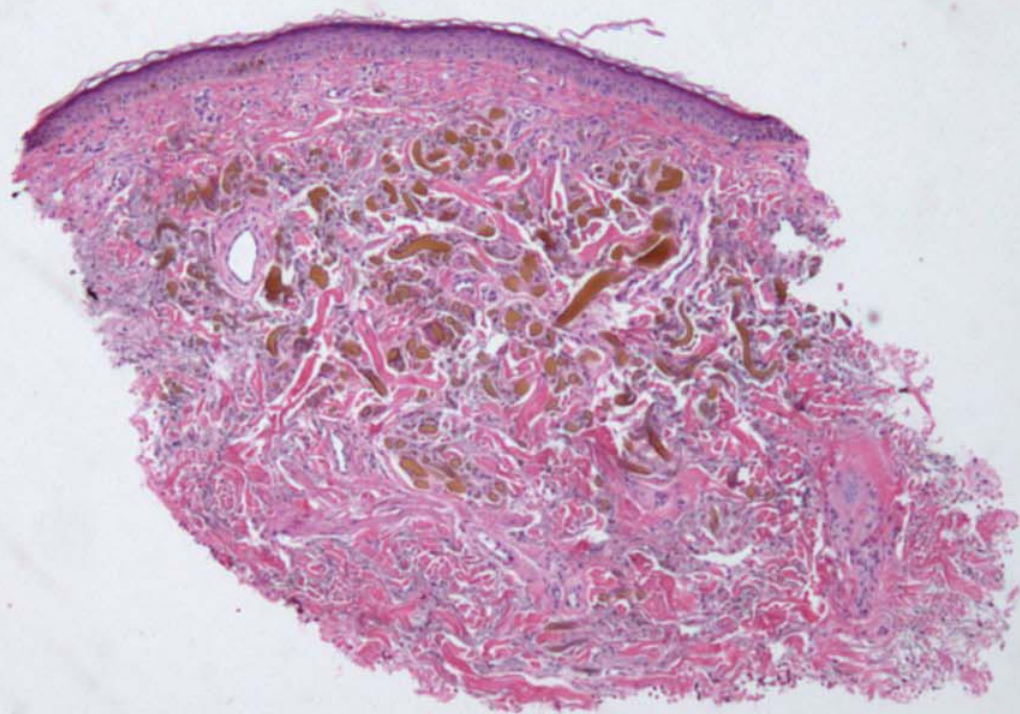
Pathology Inc.



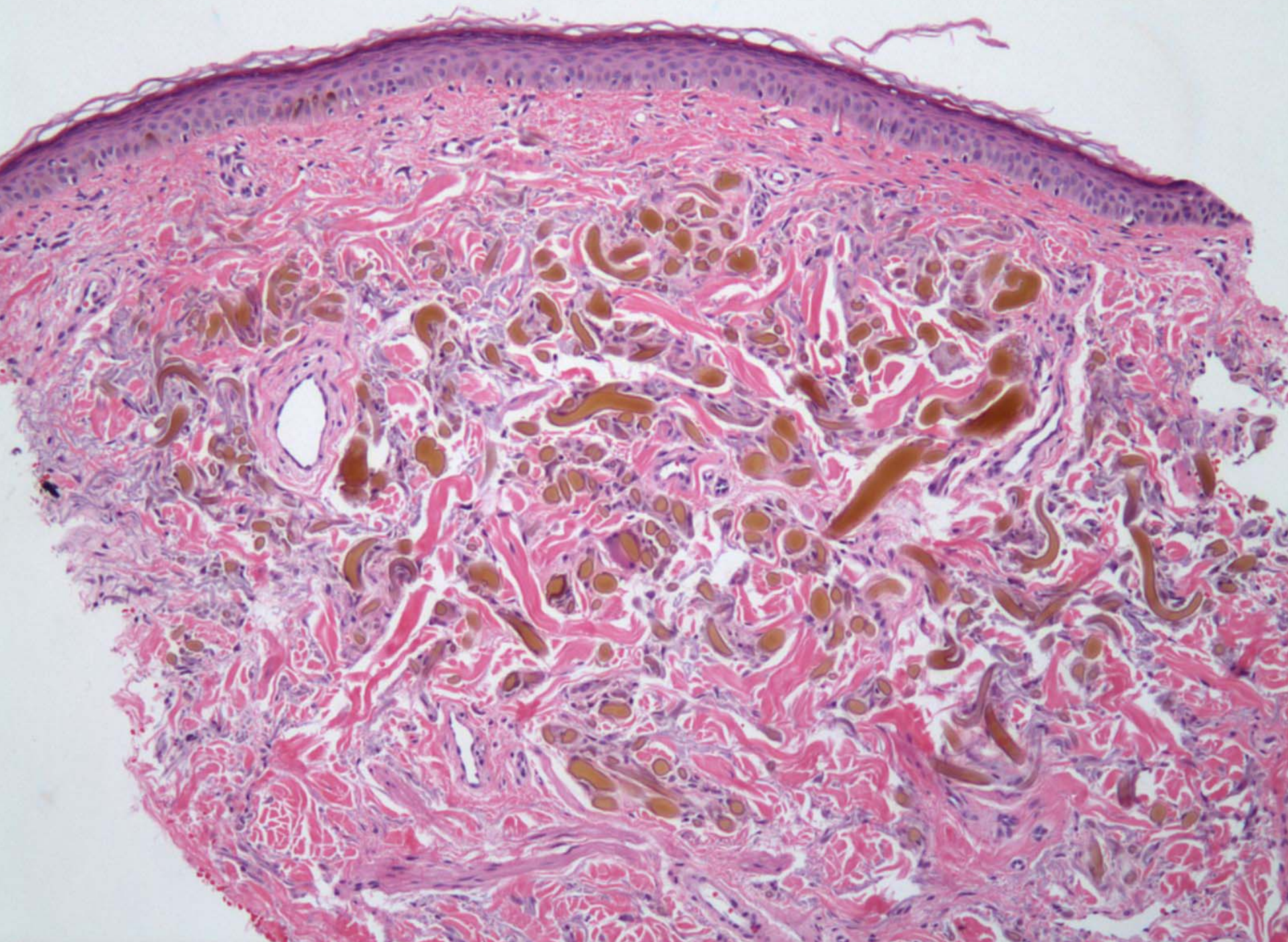
# Fun and Games



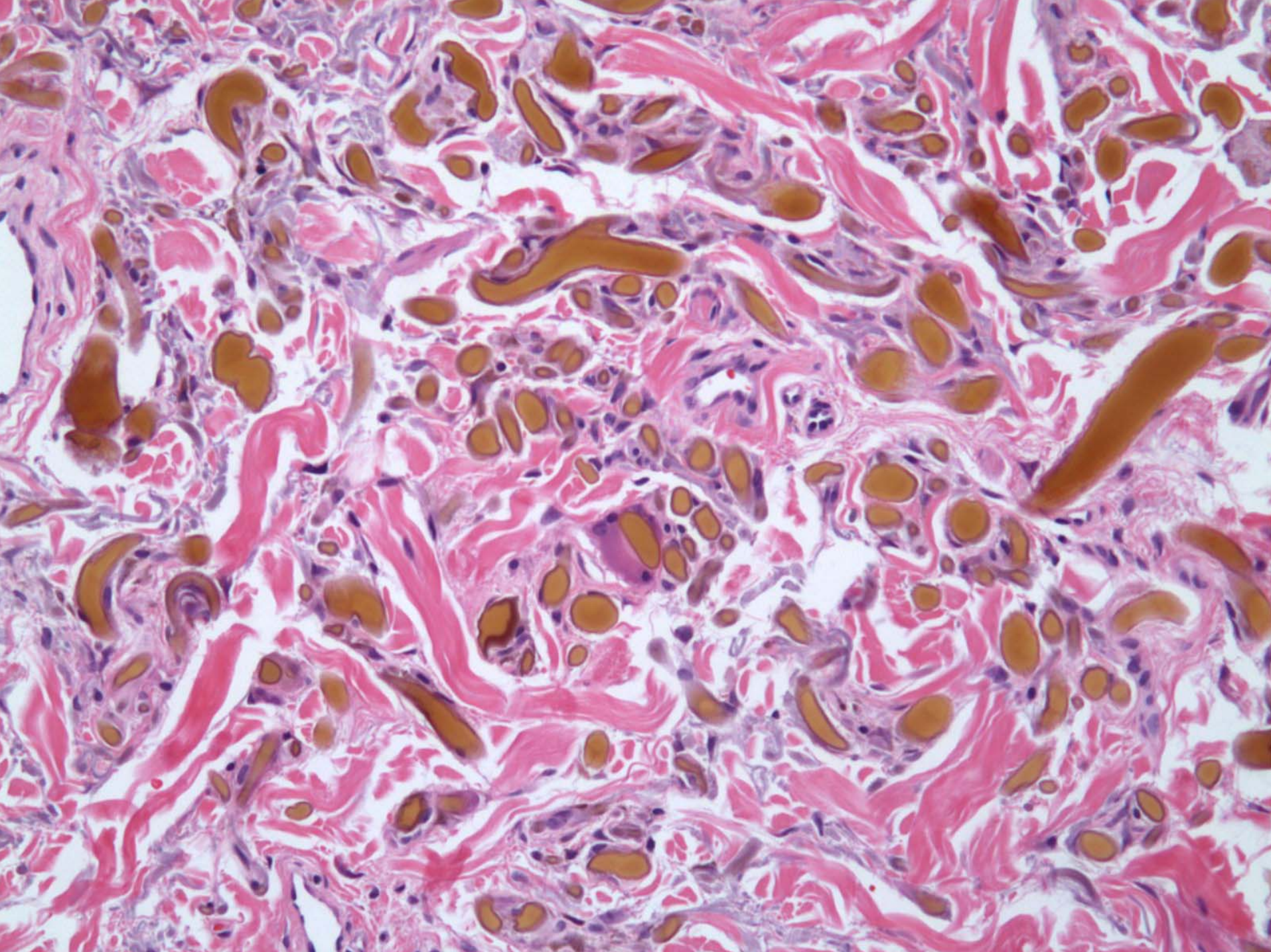




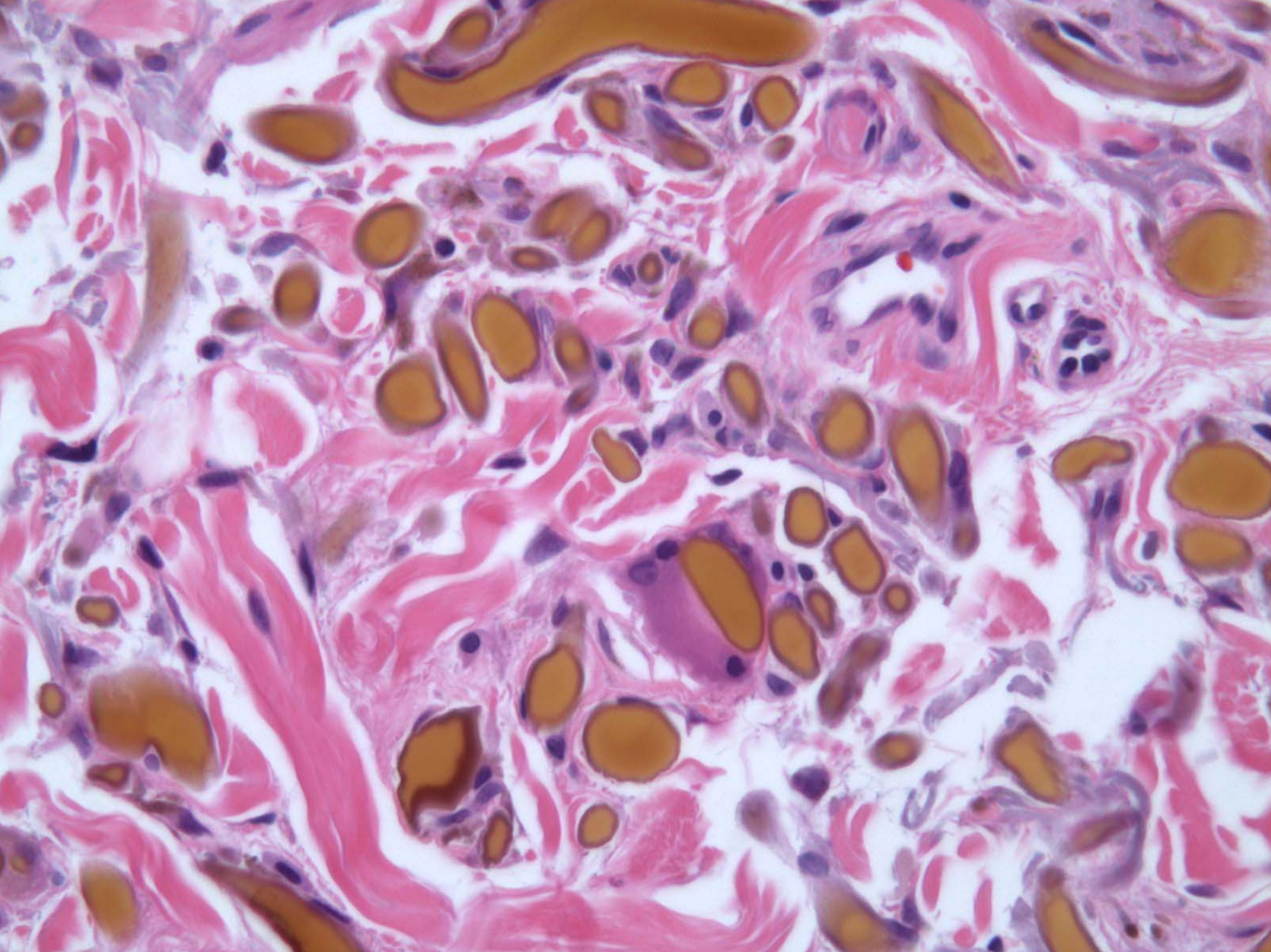




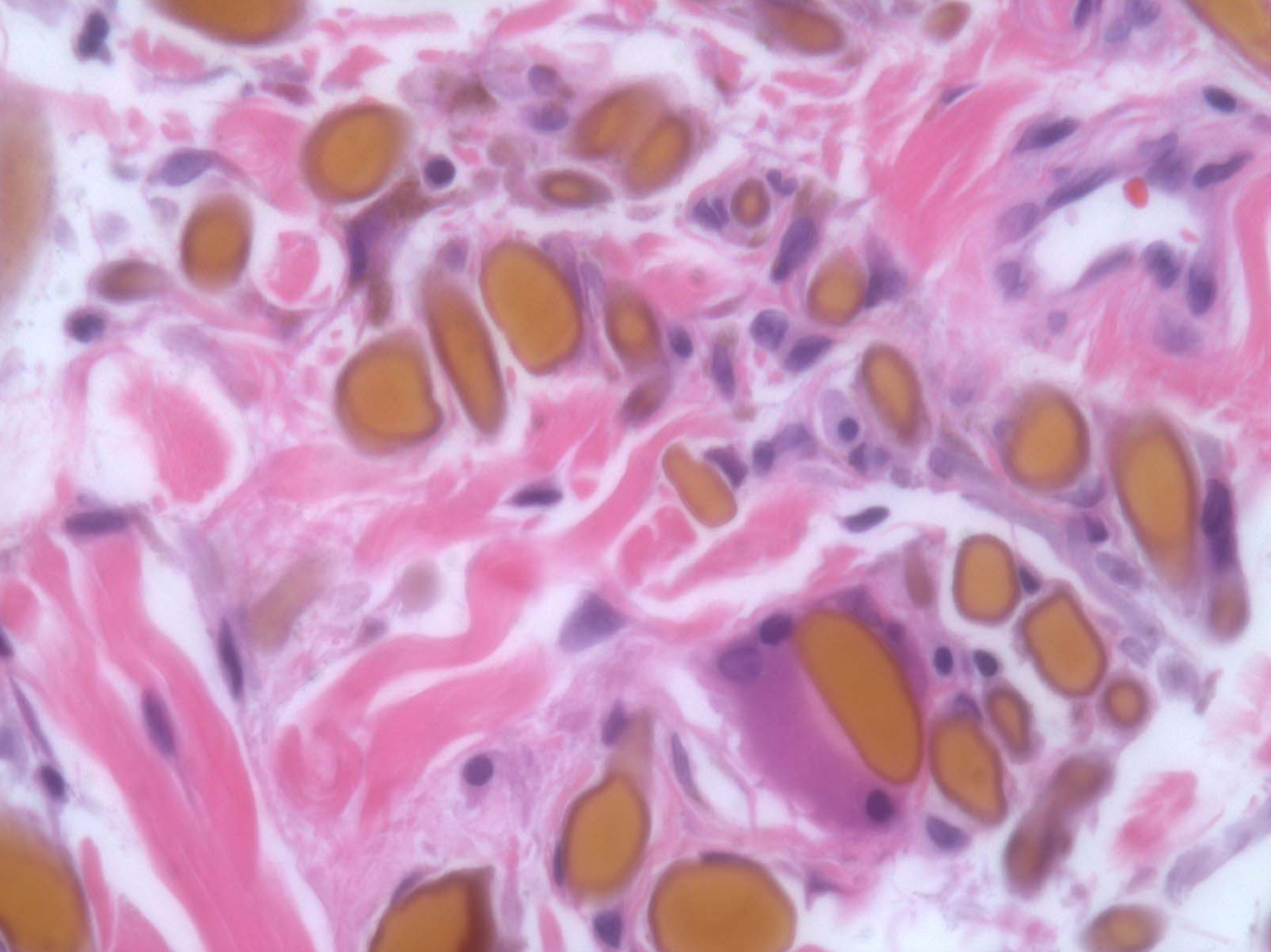






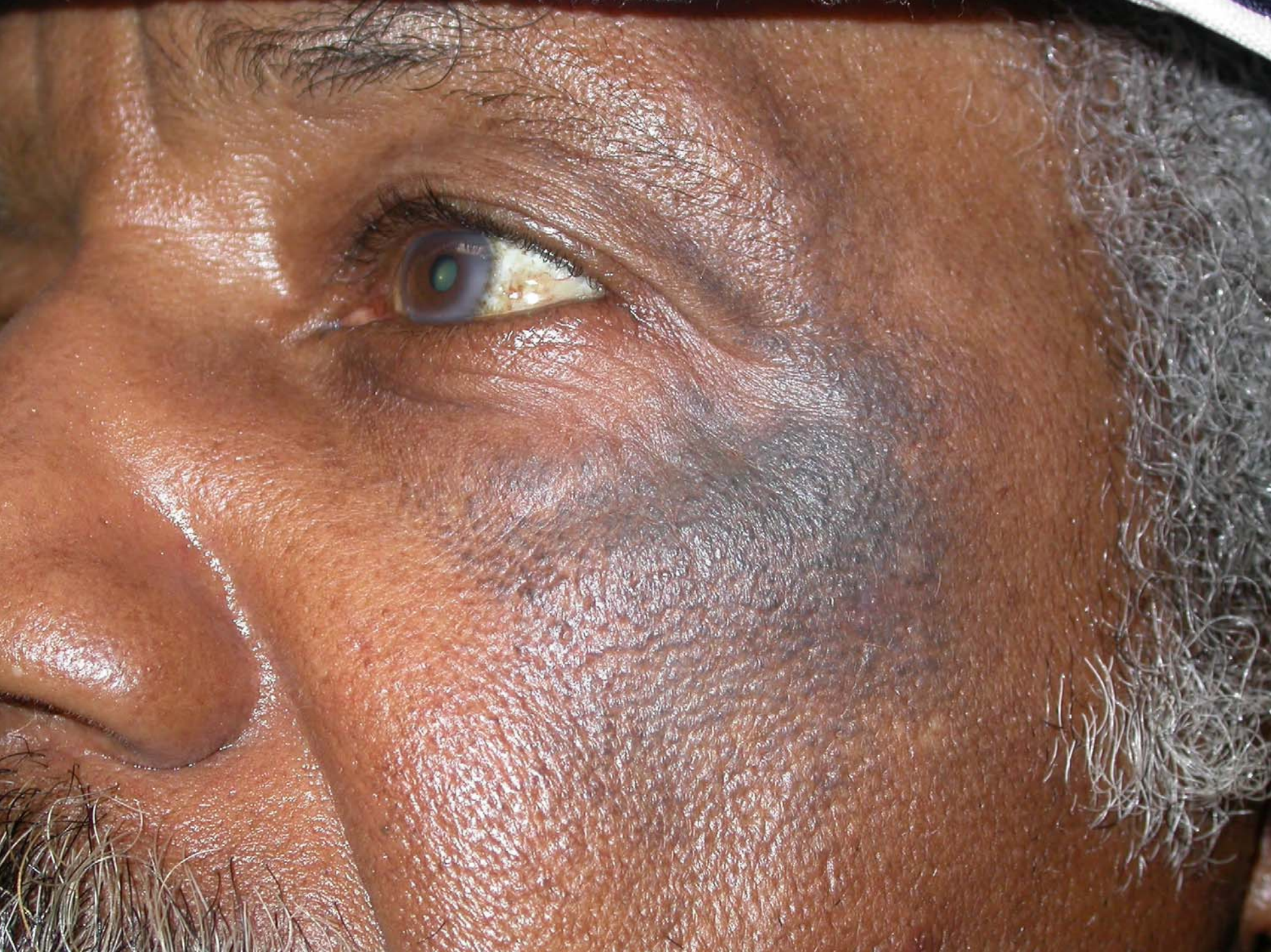





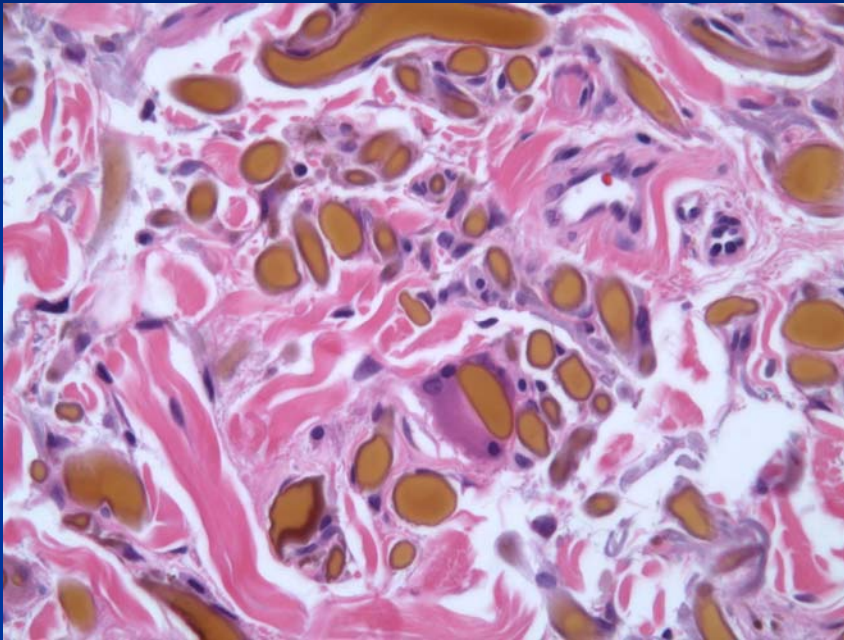
# Ochronosis





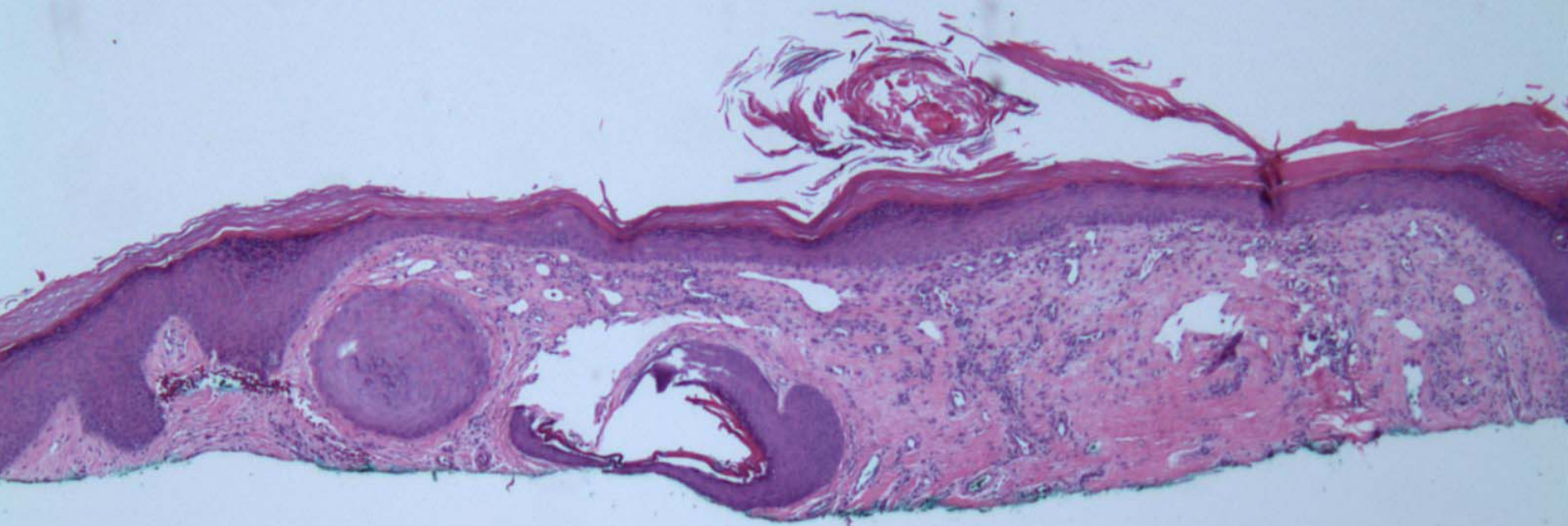


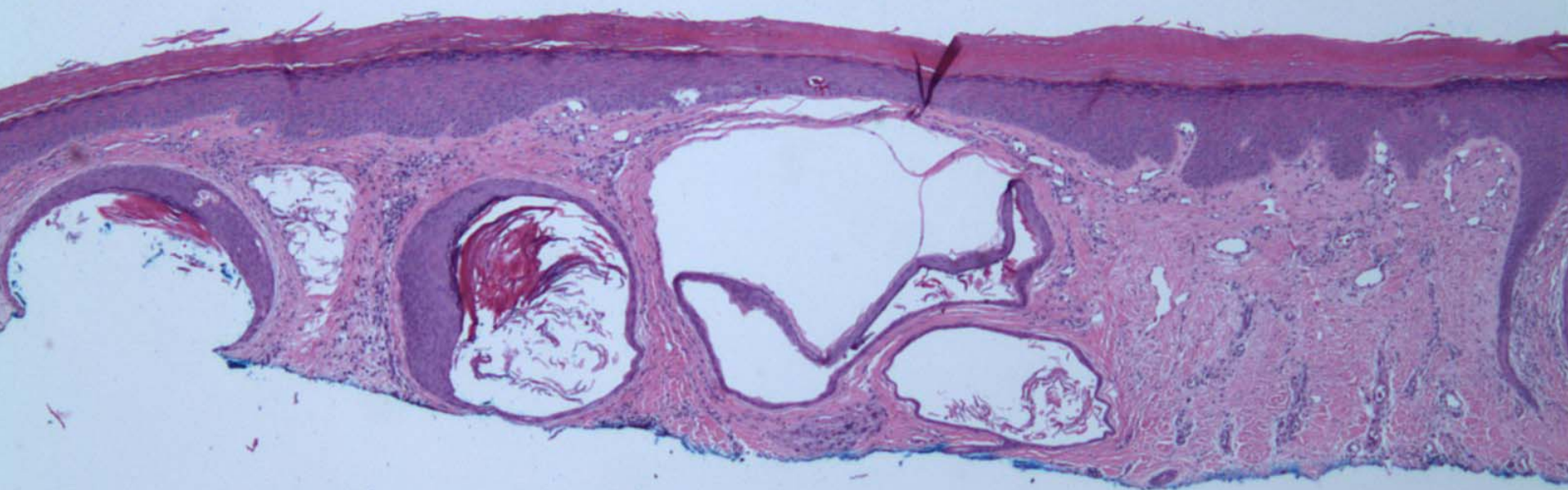
# Histopathology



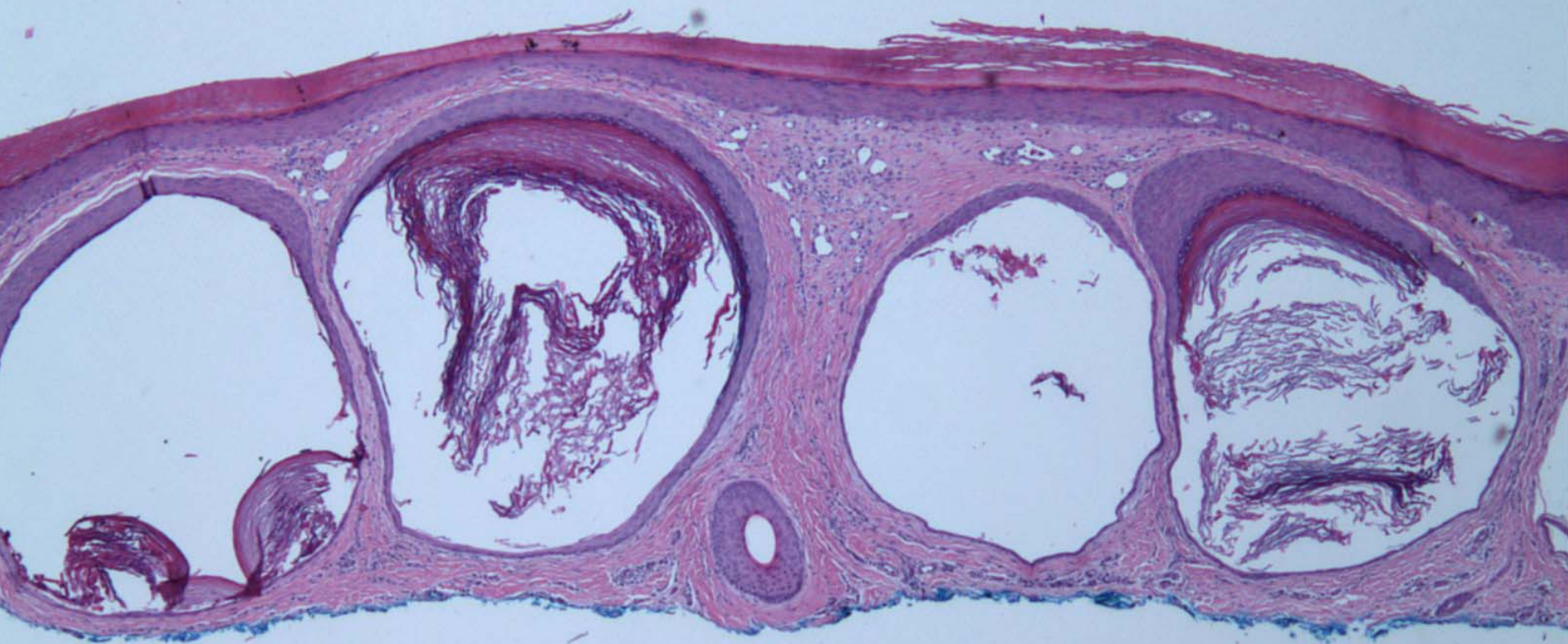
- Characteristic yellow-brown deposits (banana shaped)
- In primary cases-accumulation of homogentisic acid
- Associated with:
  - Hydroquinone
  - Anti-malarials
  - Resorcinol
  - Phenol
  - Mercury
  - Picric acid
- DDX: Primary vs. secondary



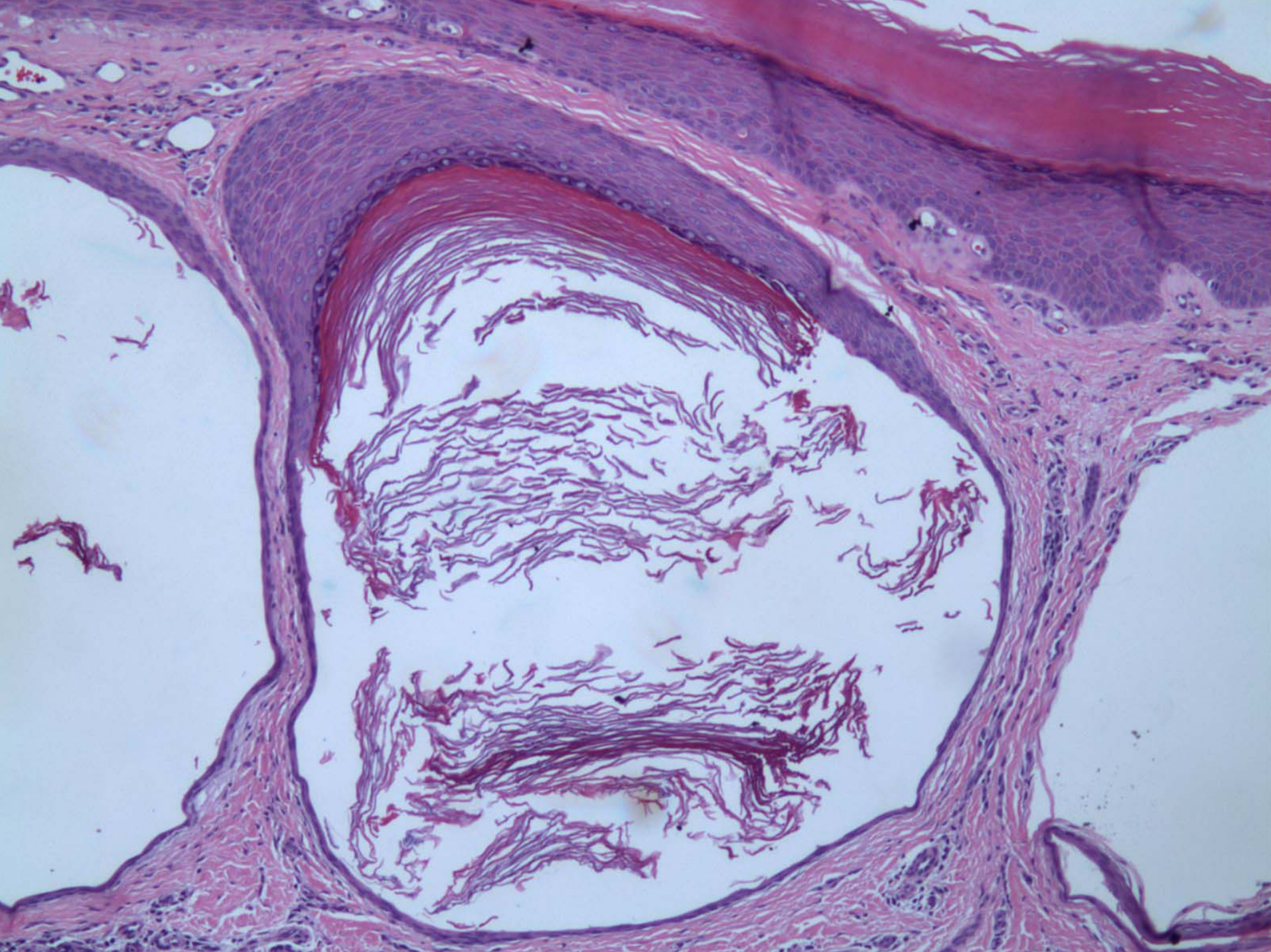




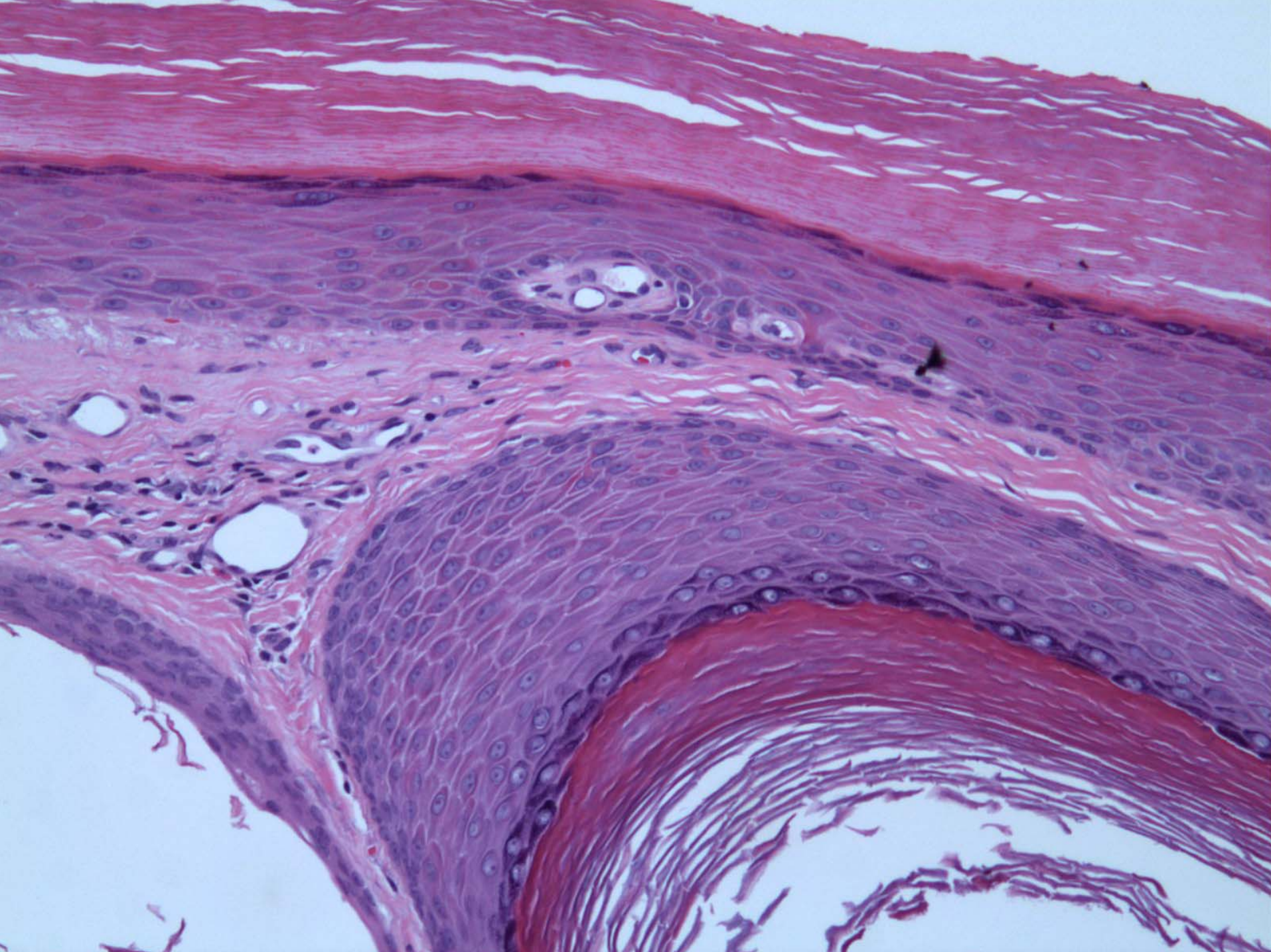




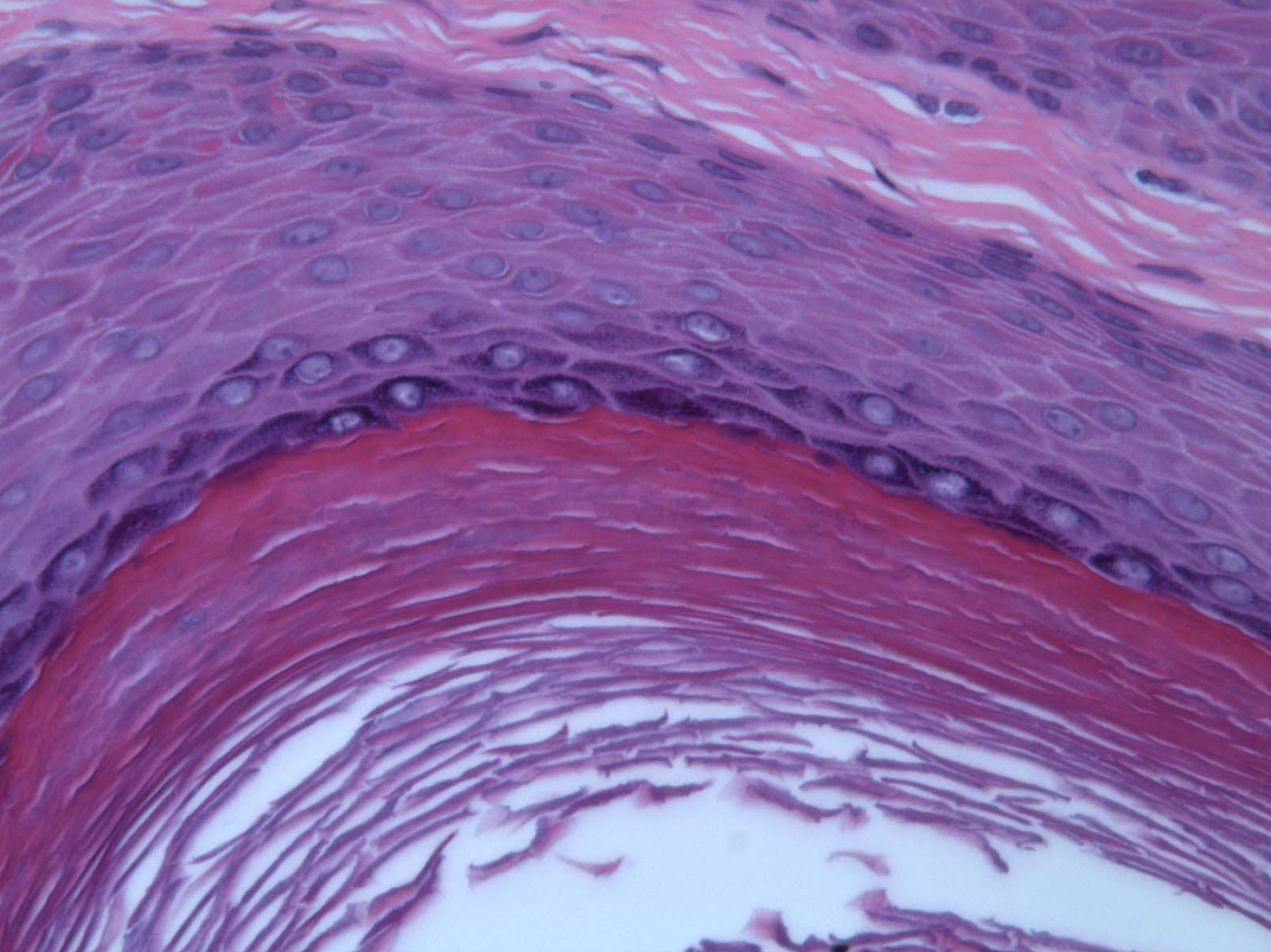








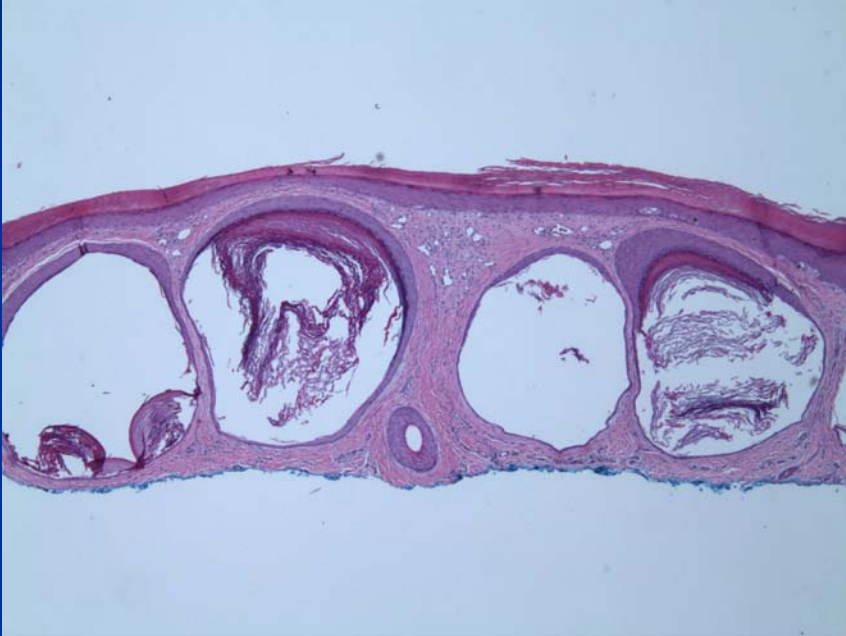



# Milia en Plaque



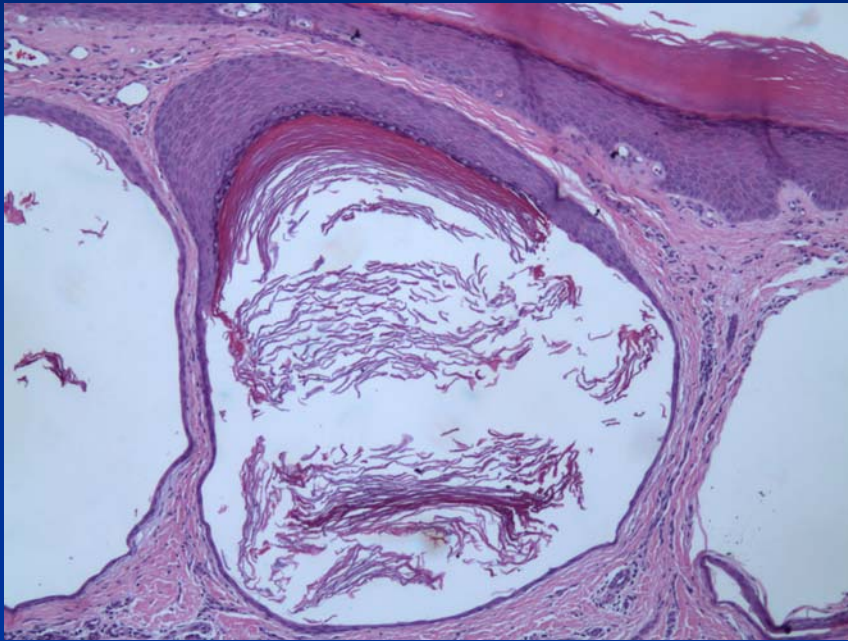
# Histopathology



- Milia (small epidermal inclusion cysts)
- Areas of rupture with scarring
- Usually on head and neck of young pts.
- Often bilateral



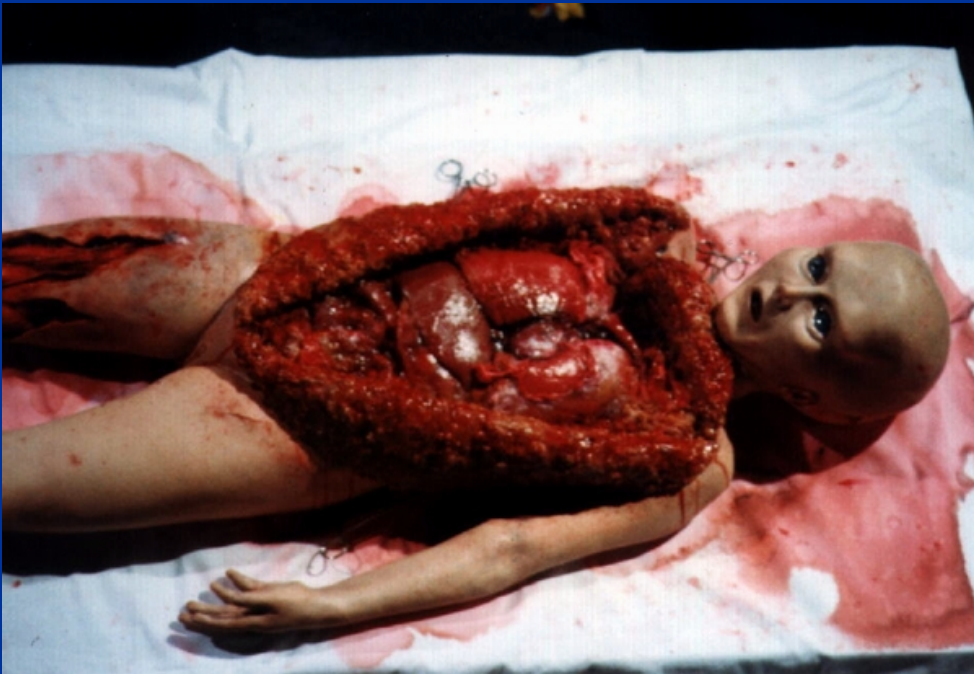# Treatment



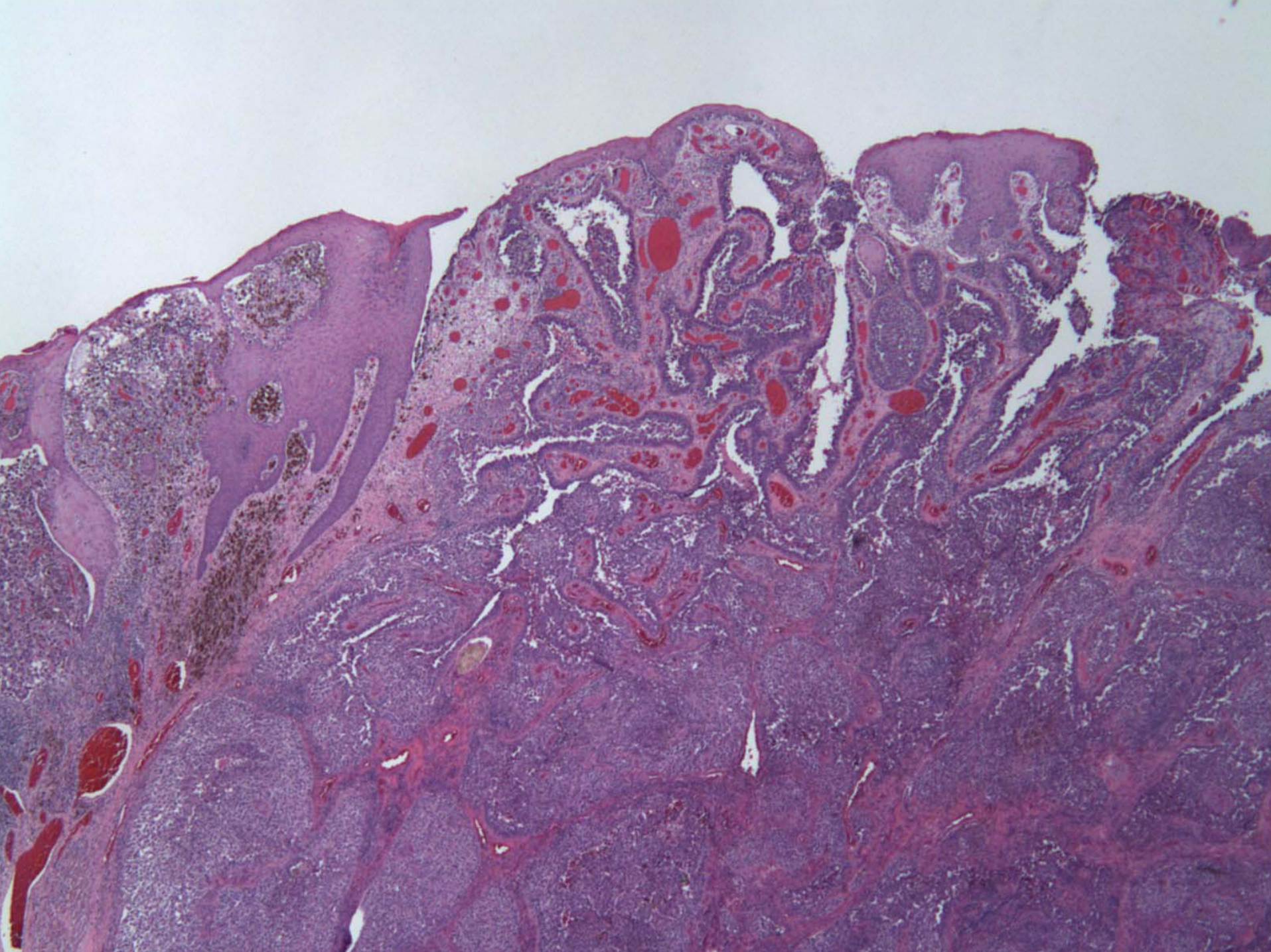
- Minocycline
- RetinA
- Dermabrasion



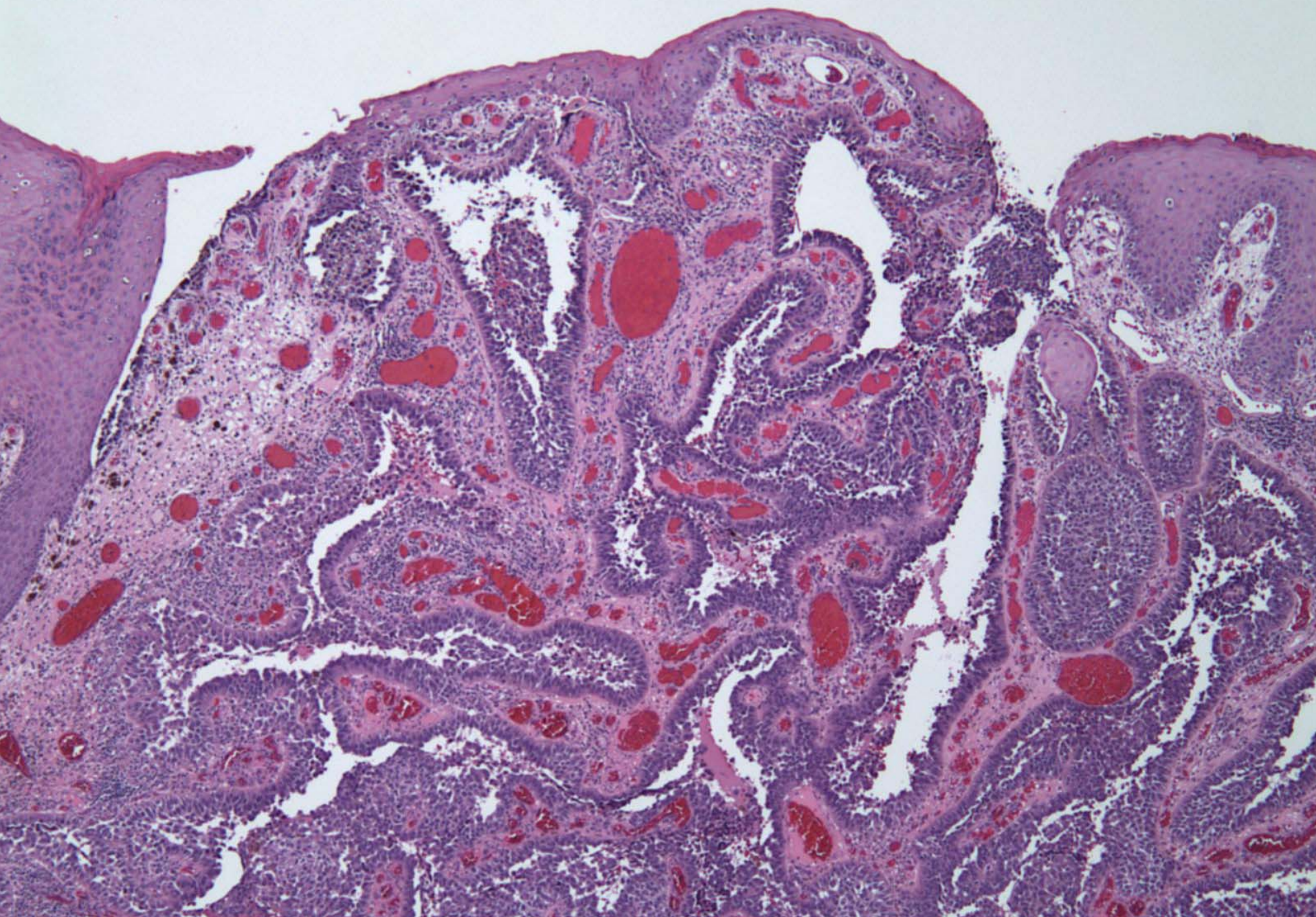
# New Diseases



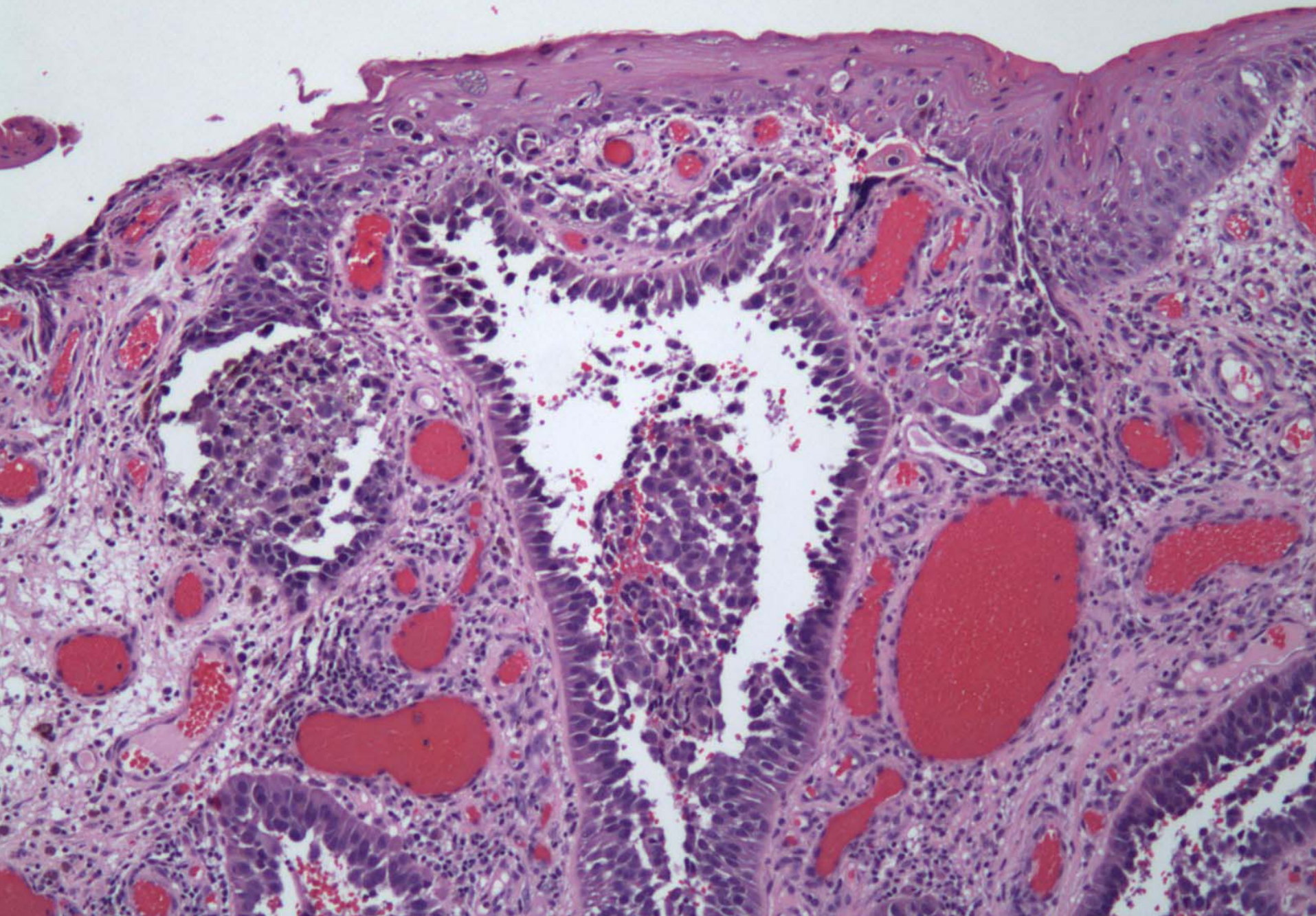




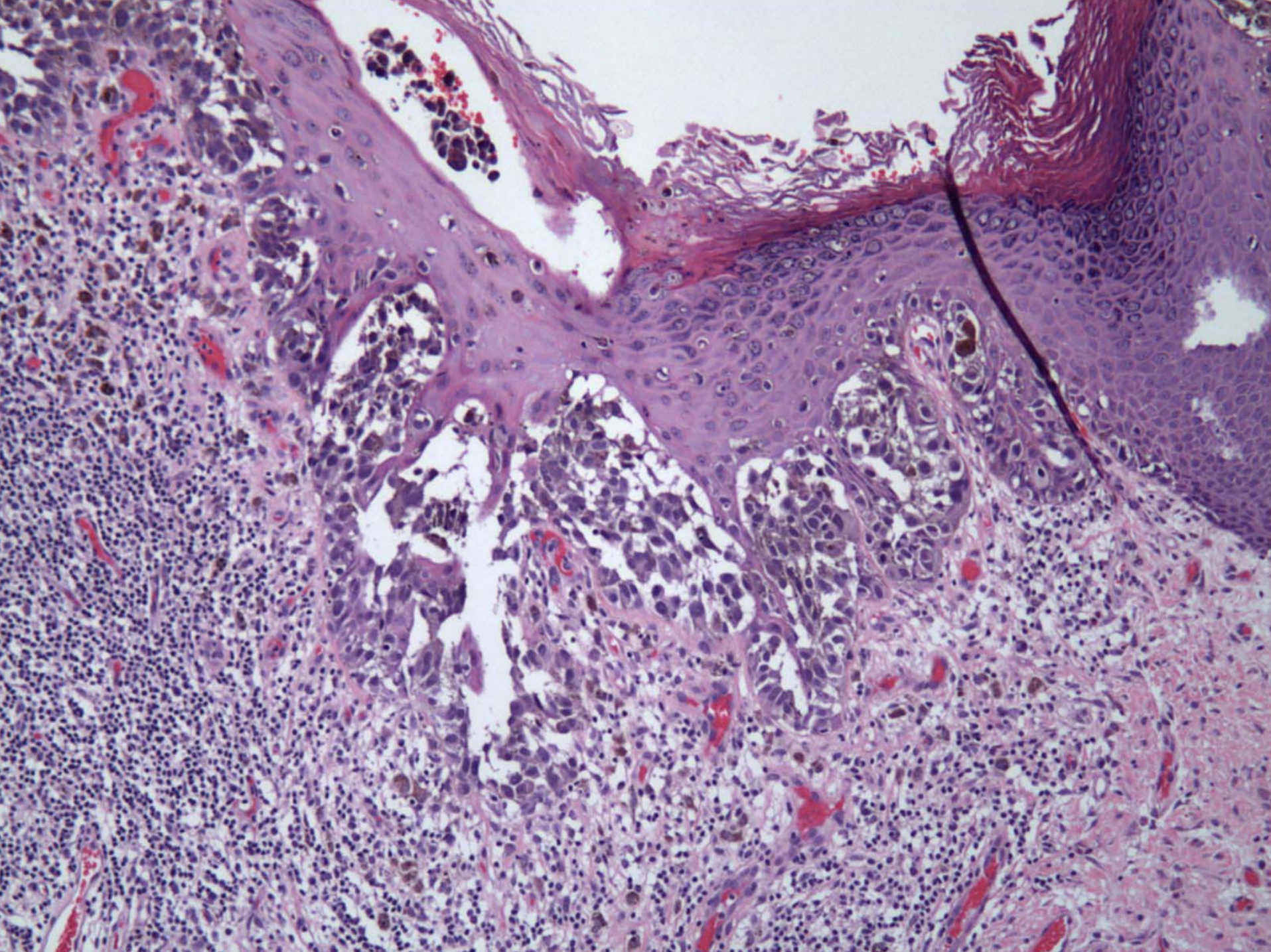




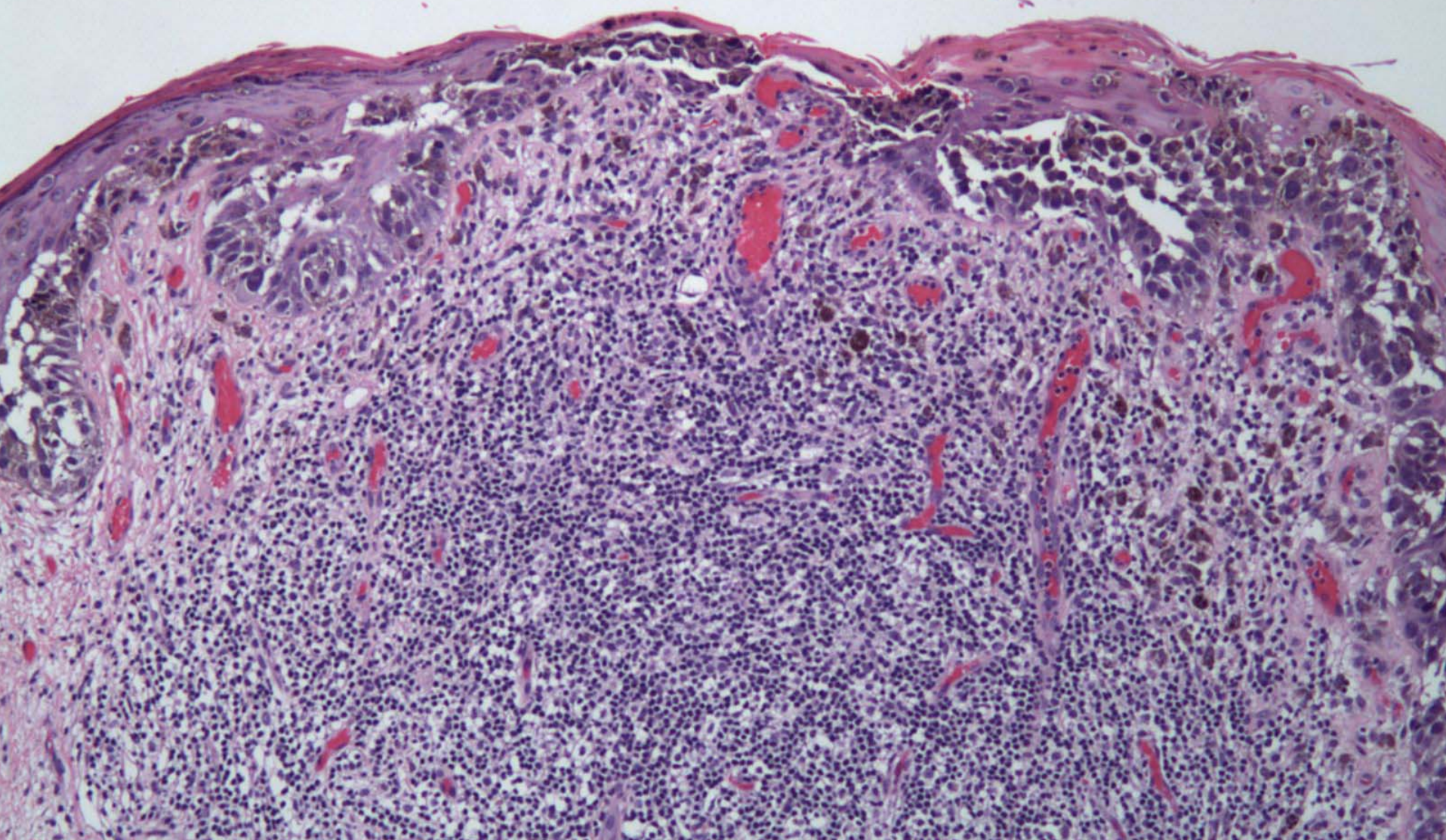




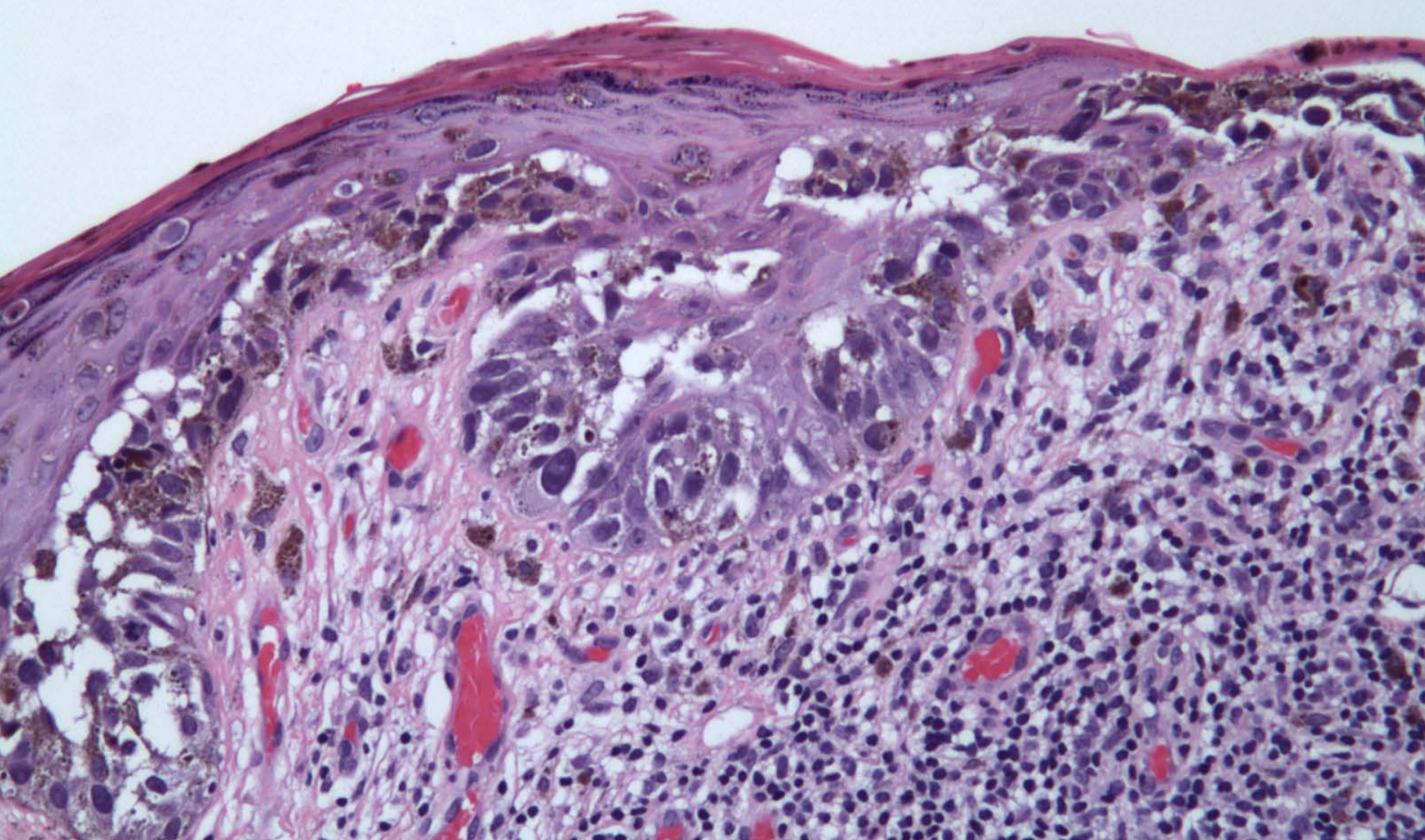




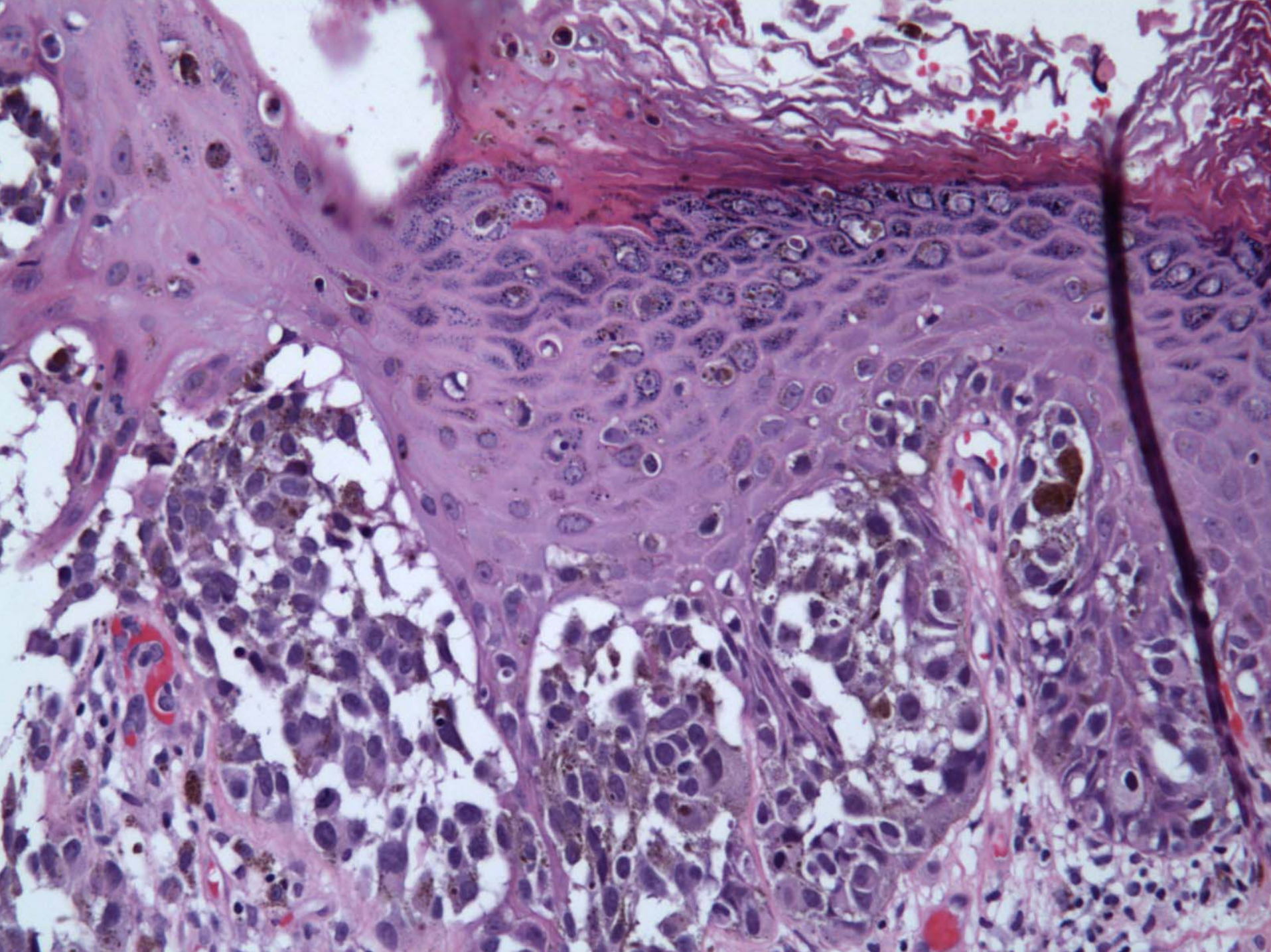




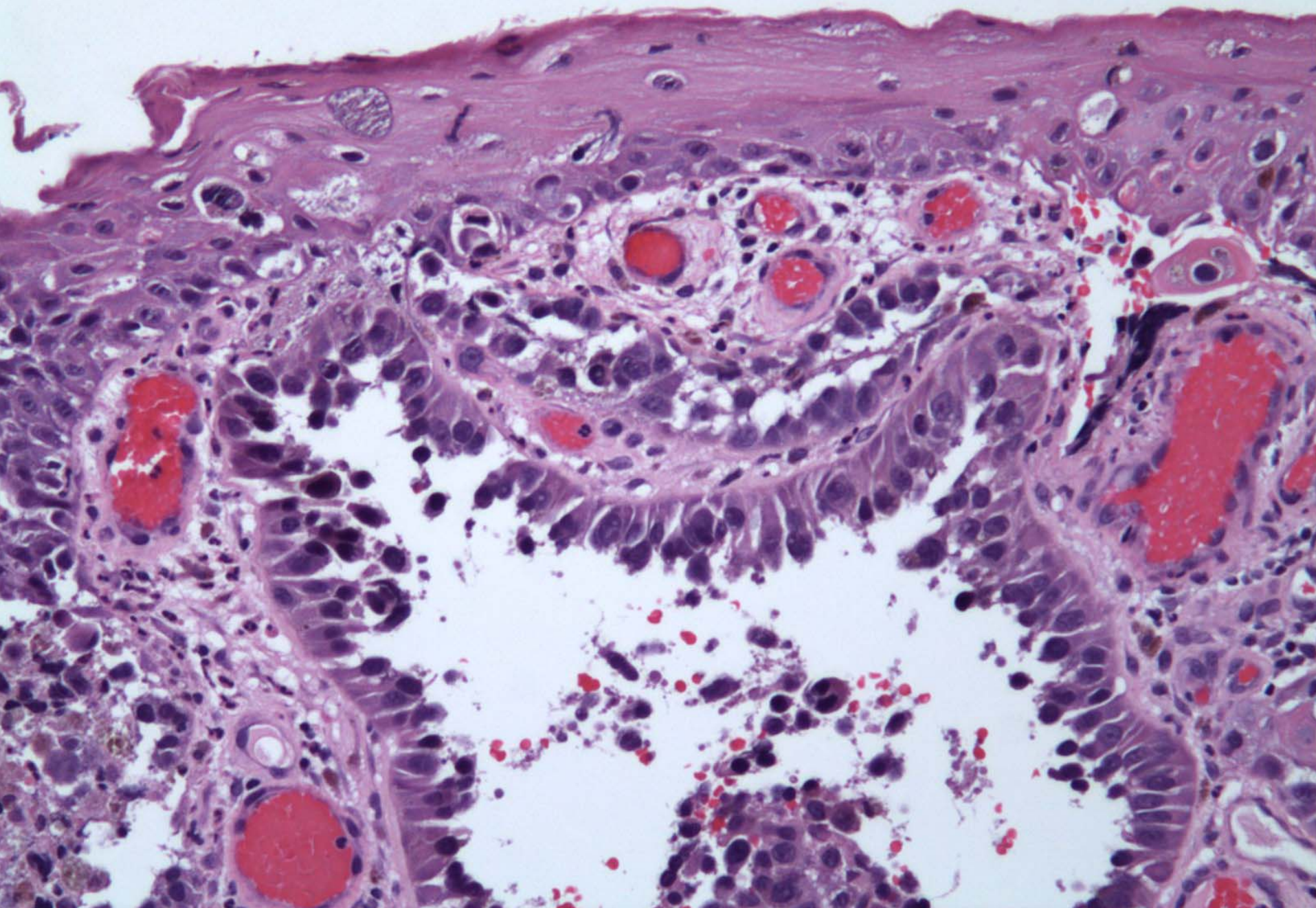




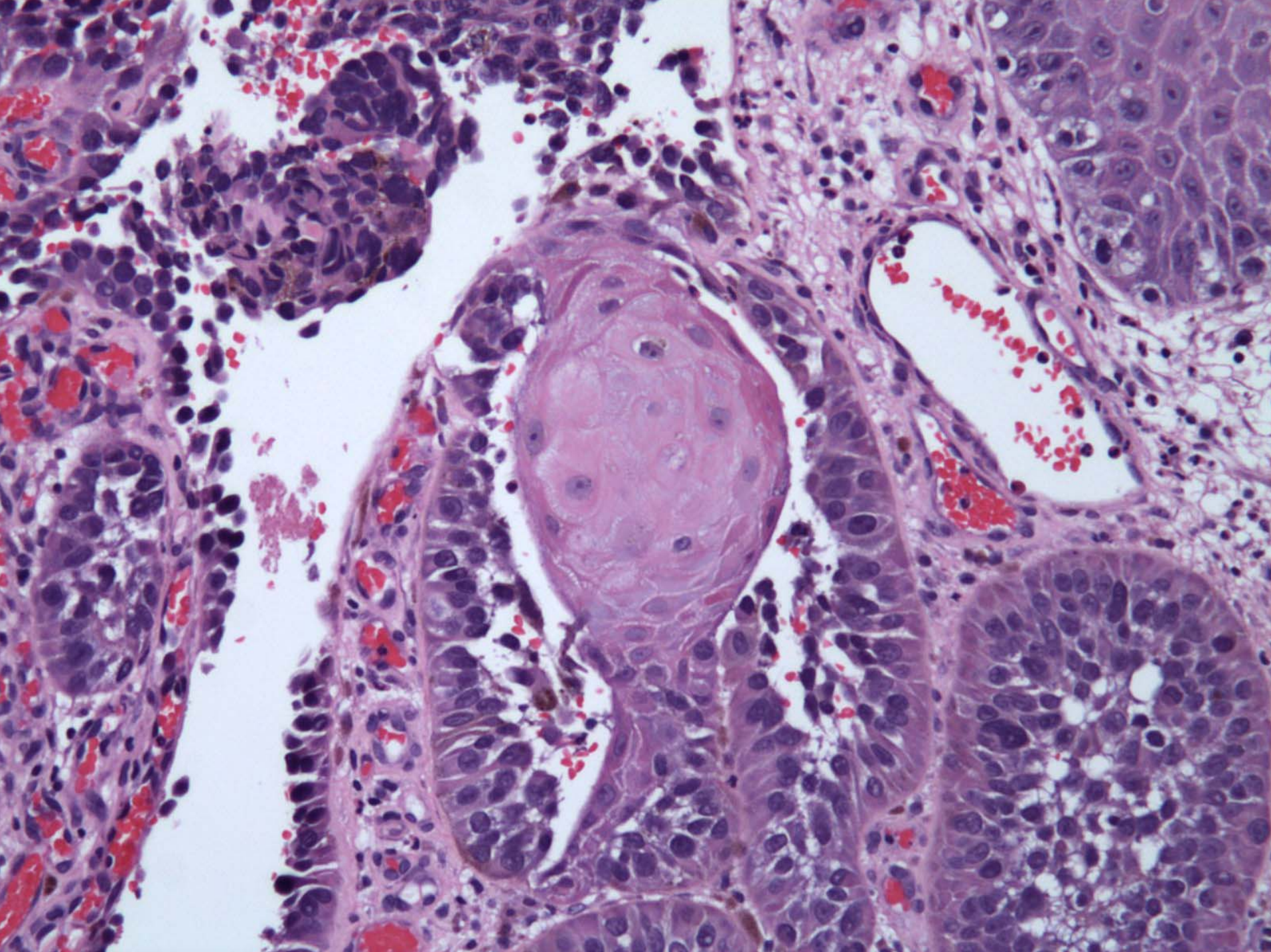




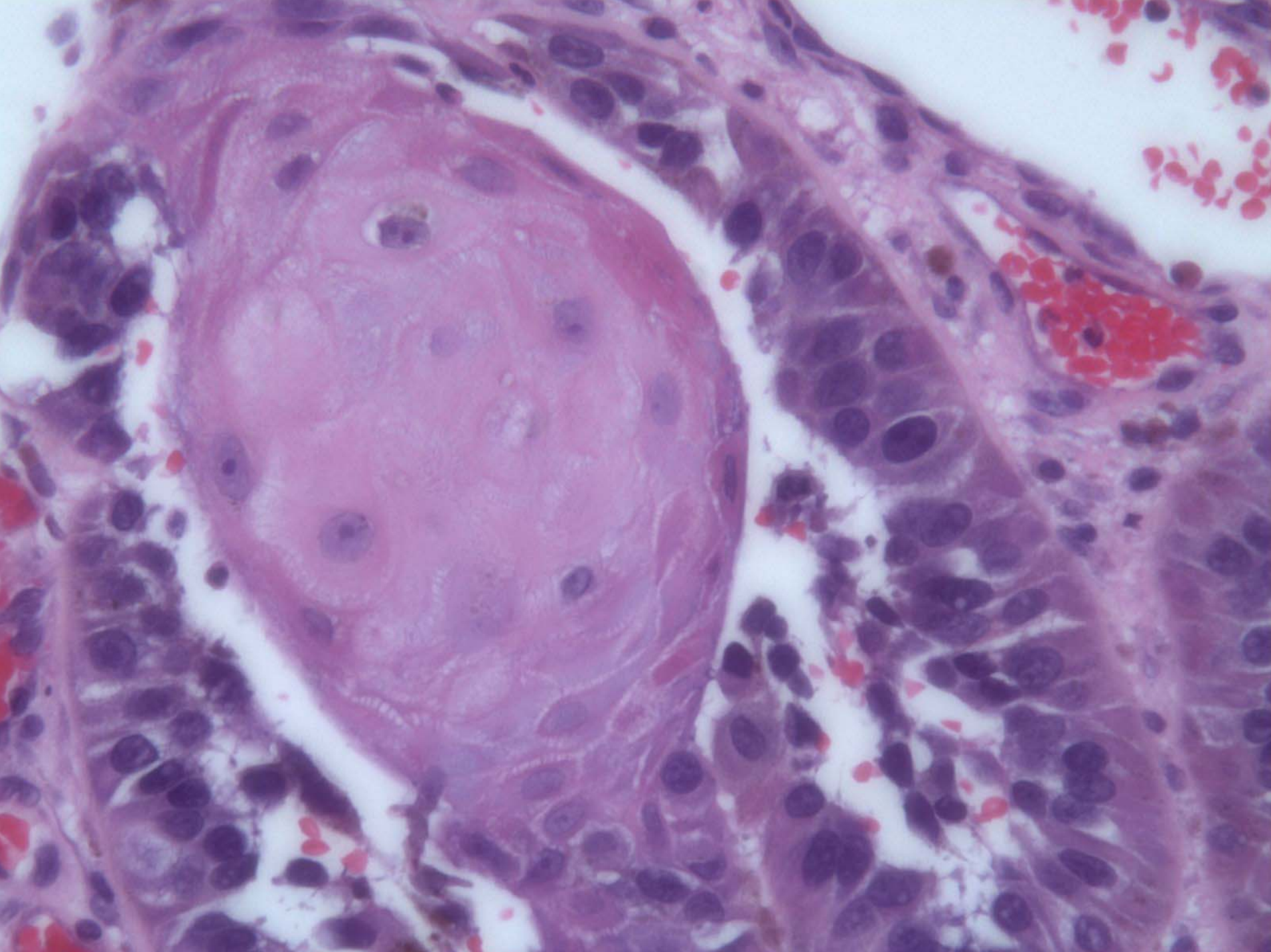




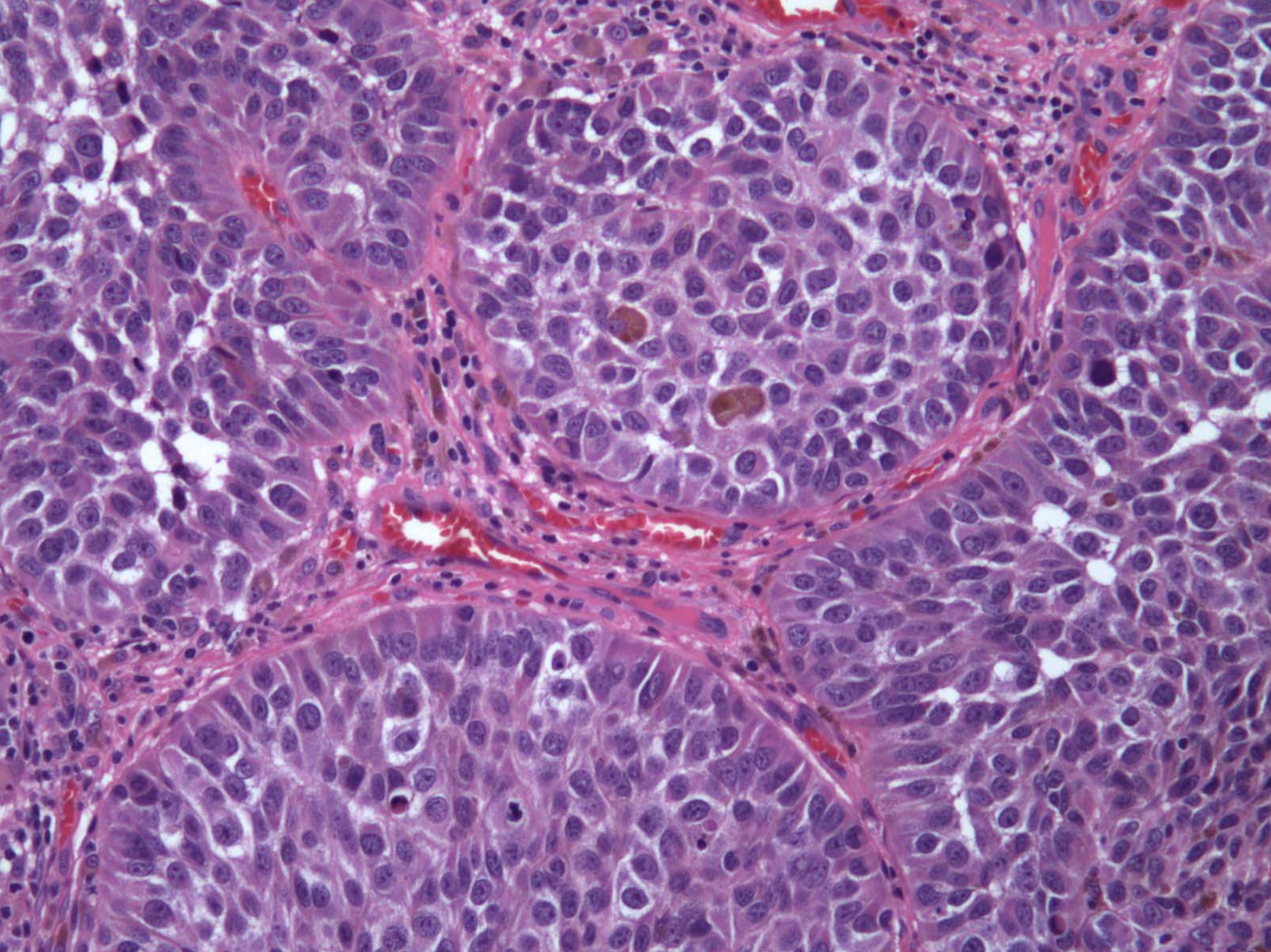




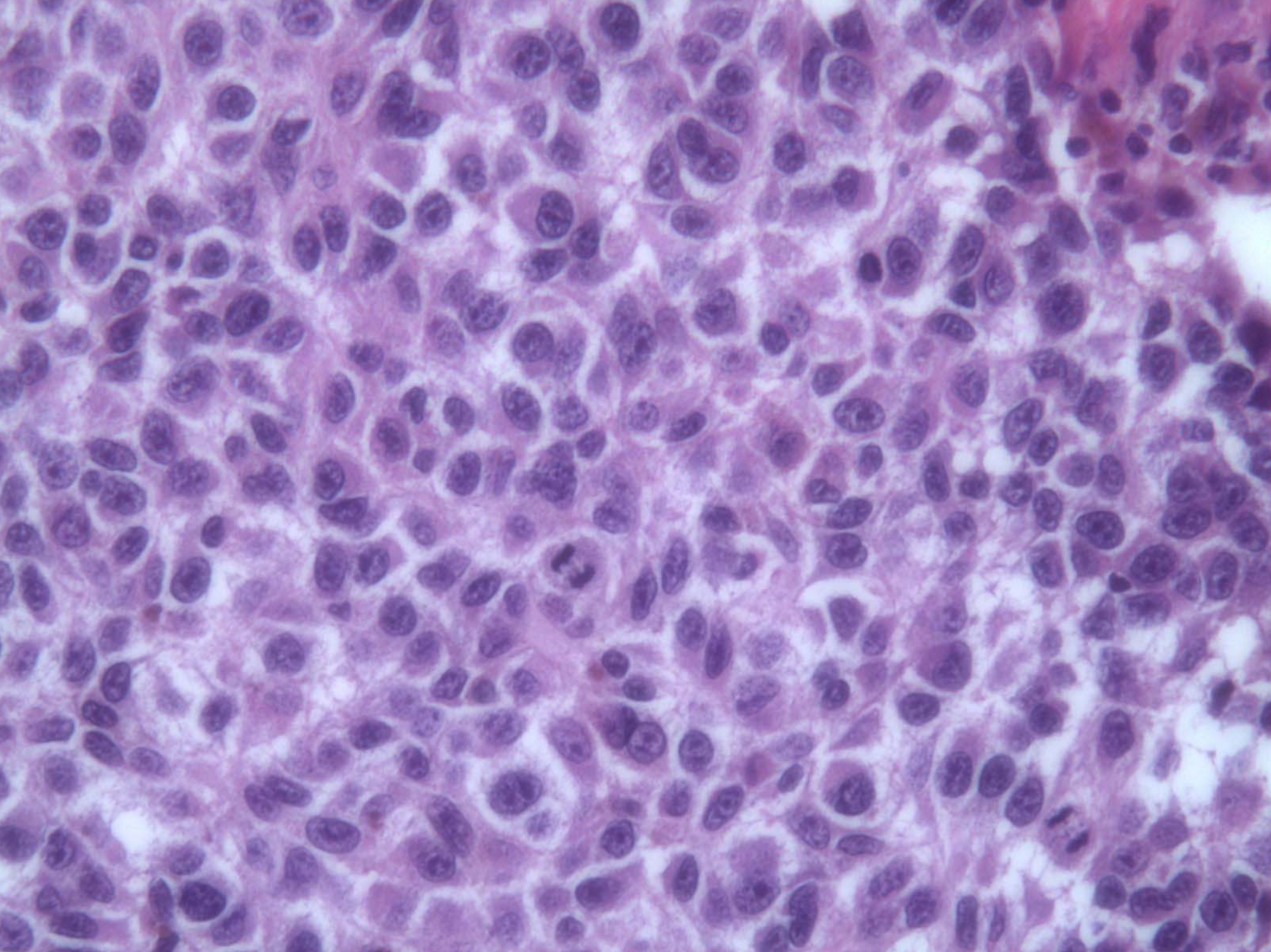




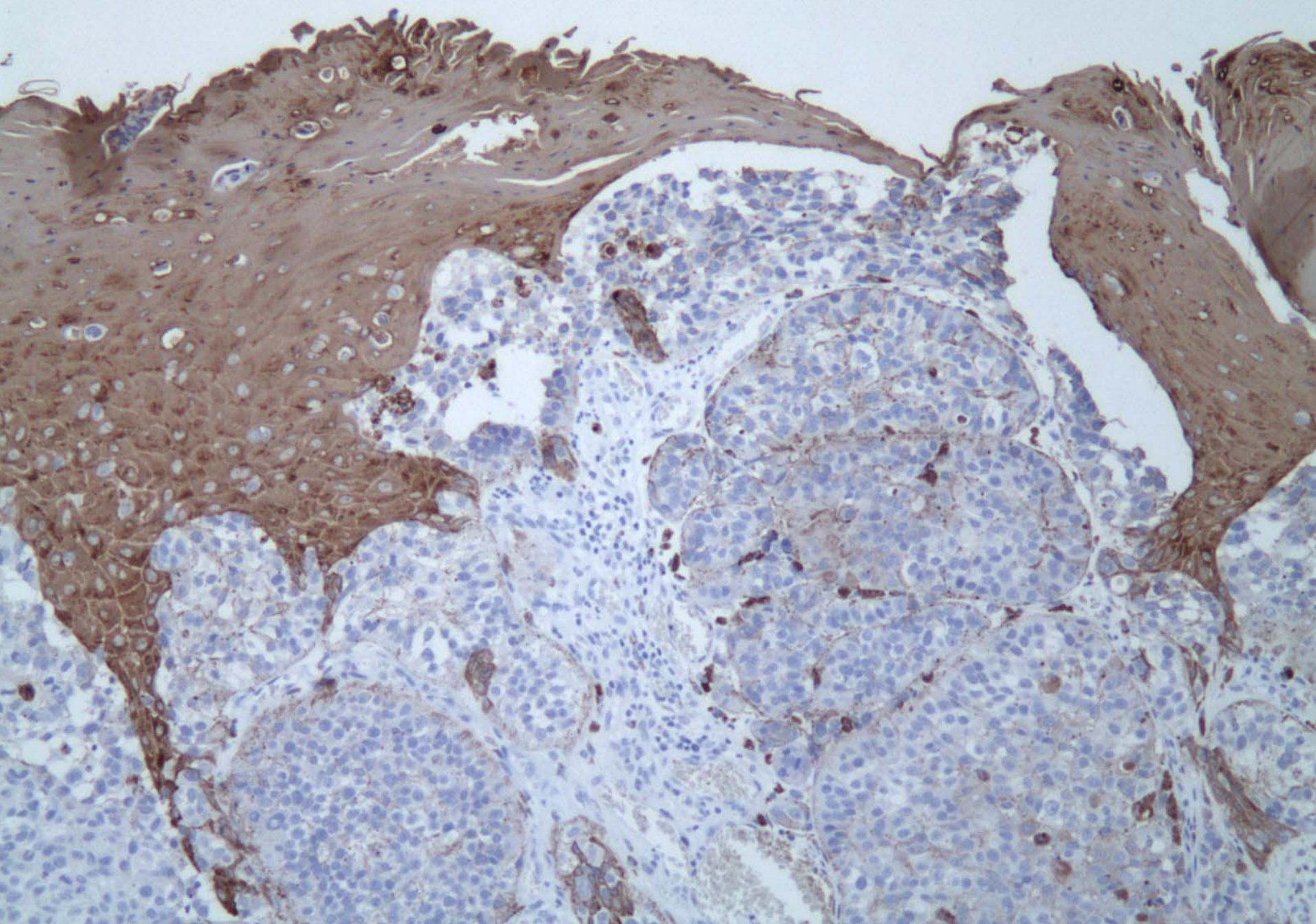




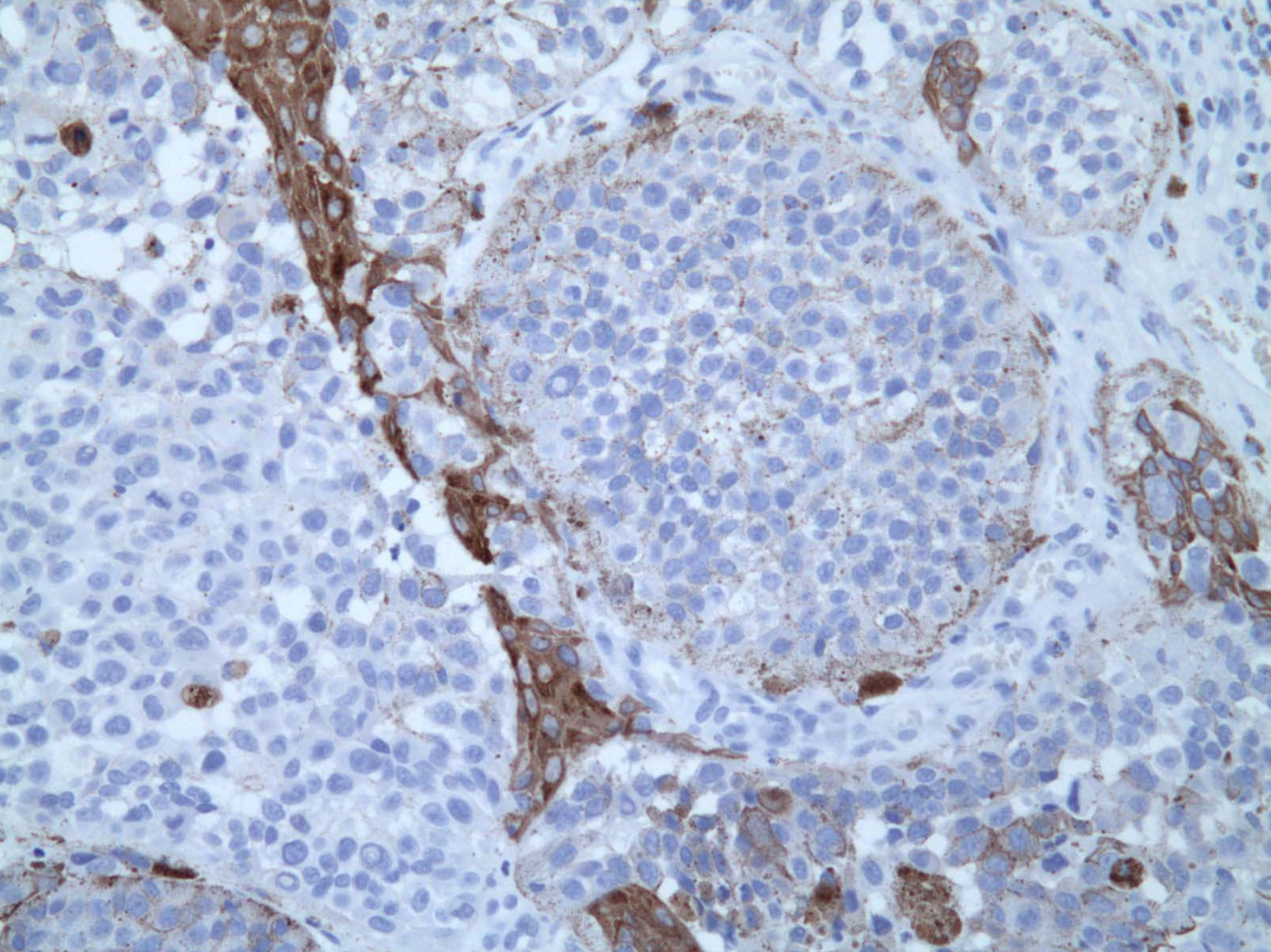




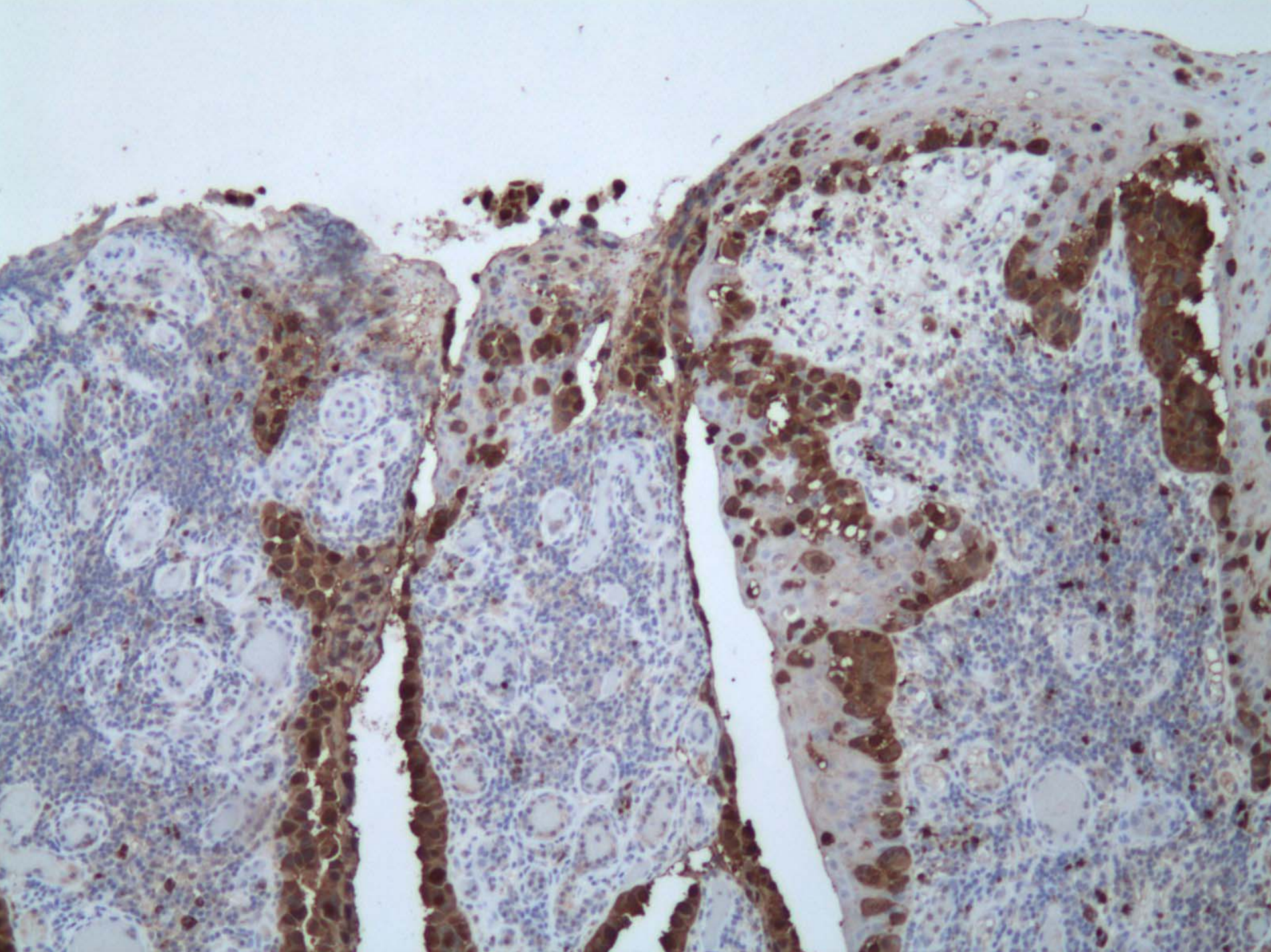




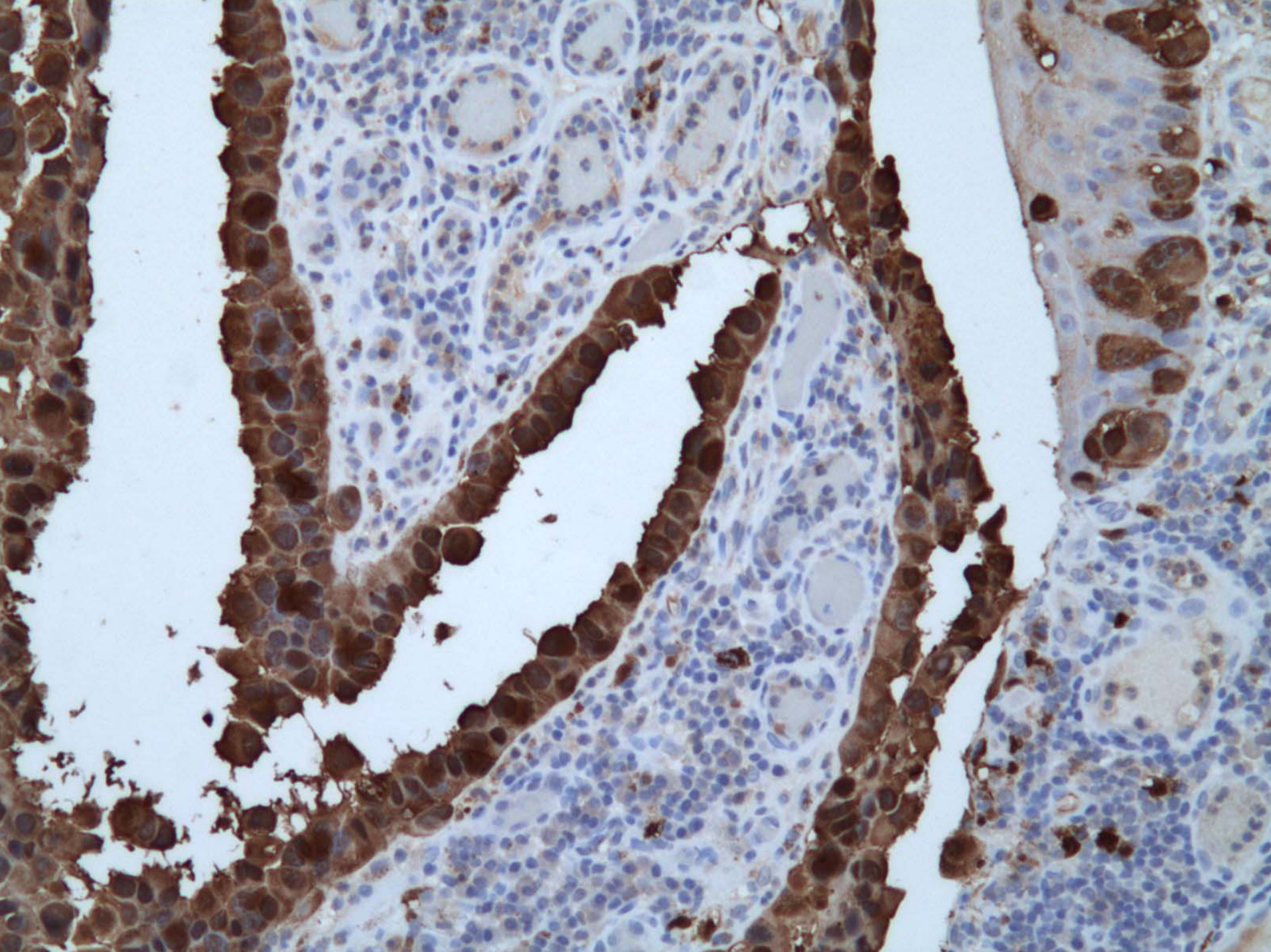




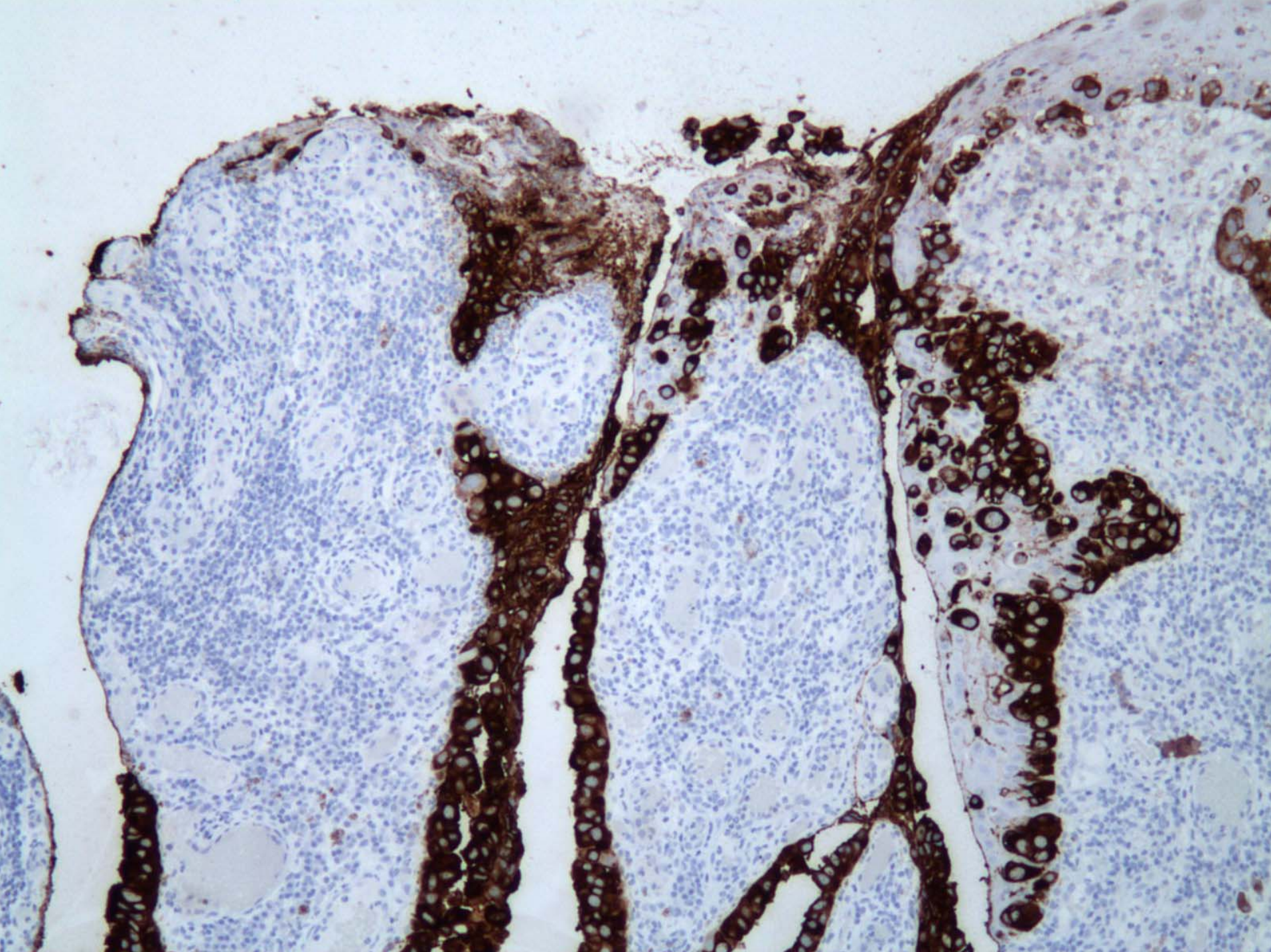




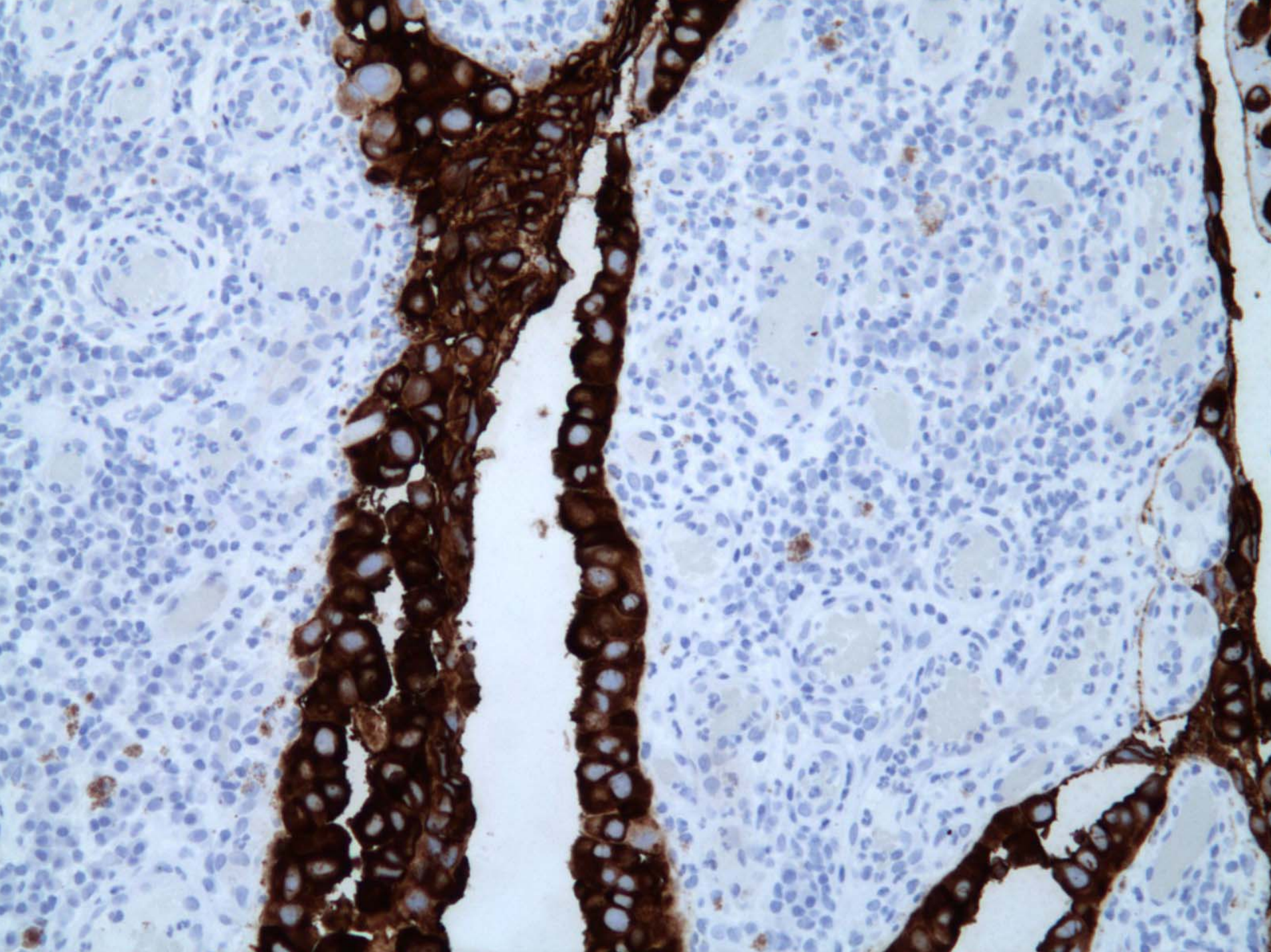










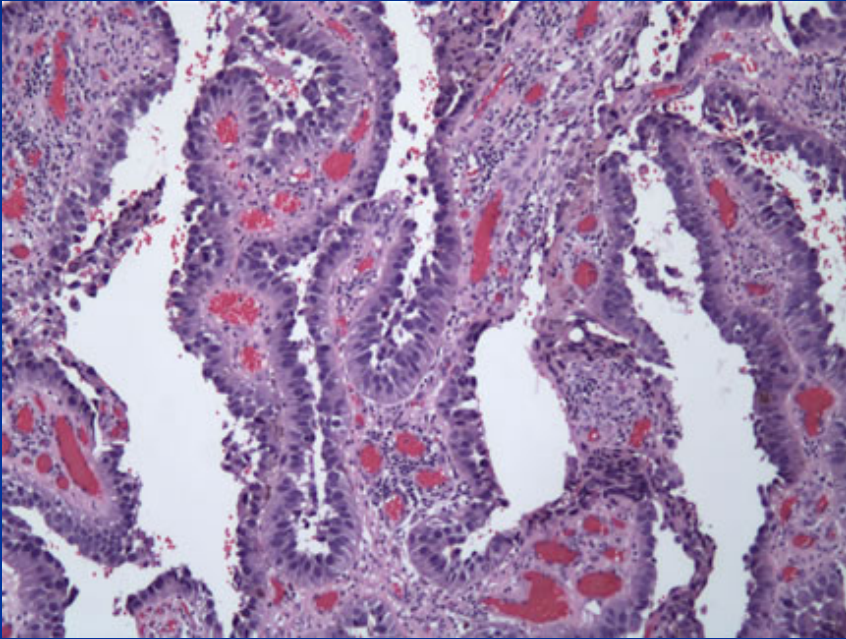




**Melanoma with  
Pemphigus-Vegetans Changes  
(Pseudoacantholysis)**

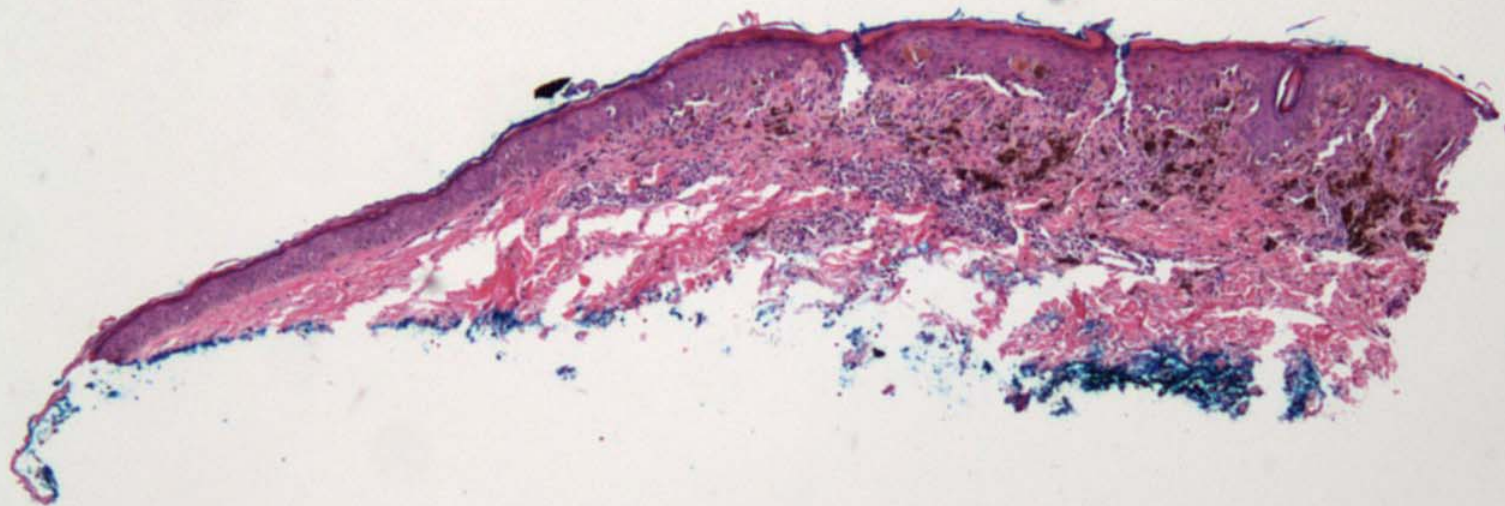


# Histopathology

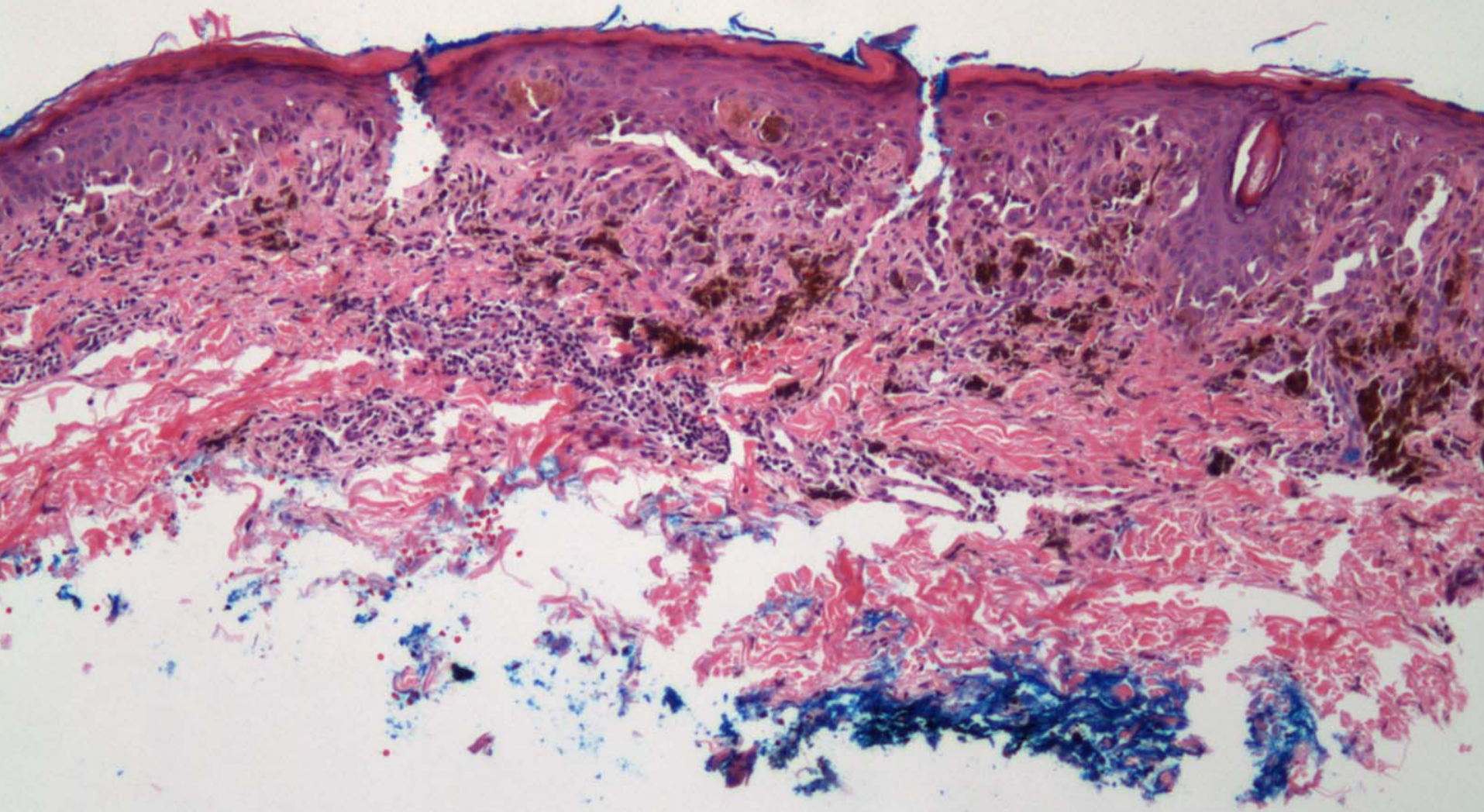


- May be extensive colonization of epidermis imparting pseudoacantholytic appearance
- Intercellular C3d and C4d negative (negative for pemphigus related antigens)

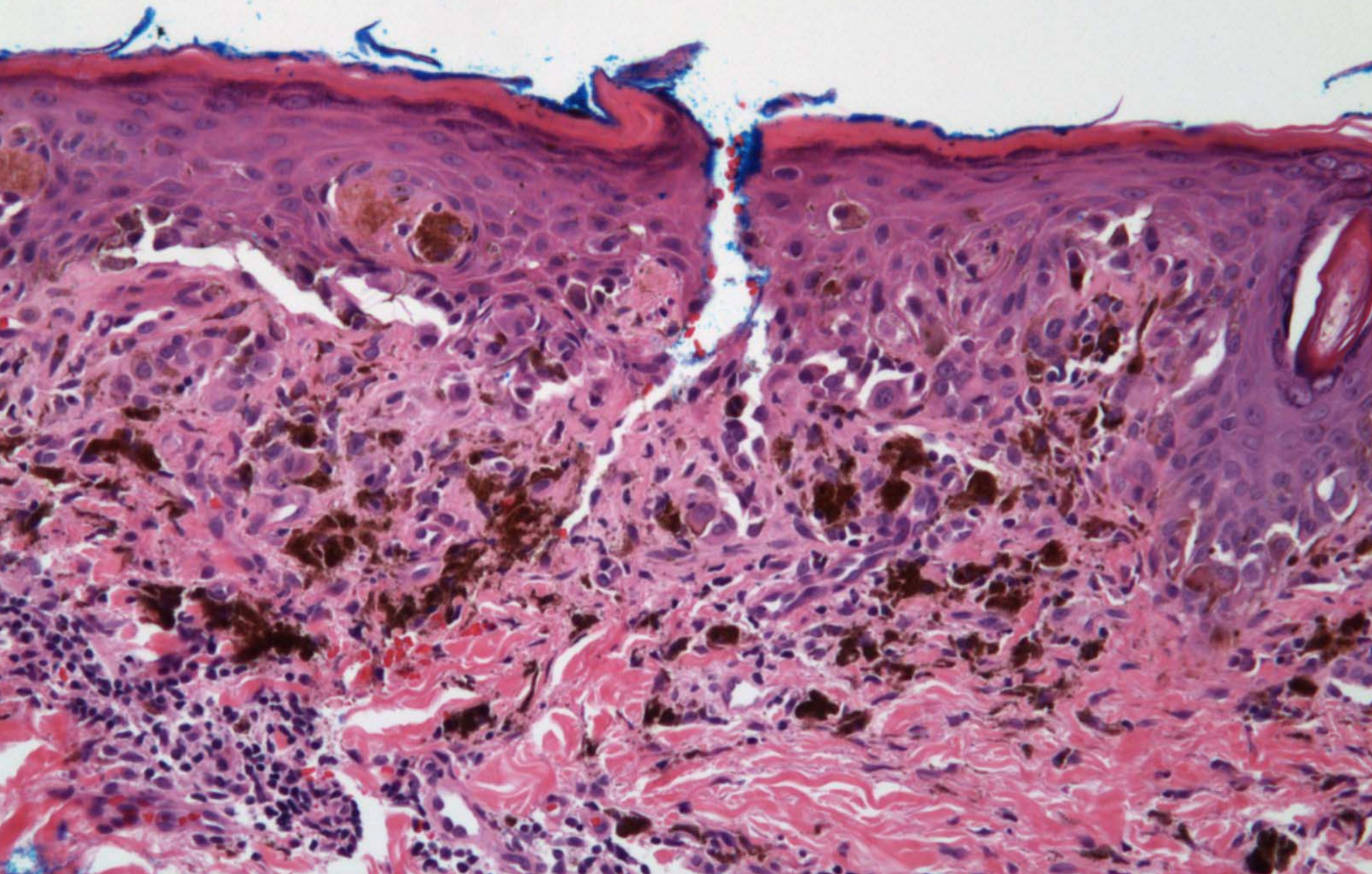




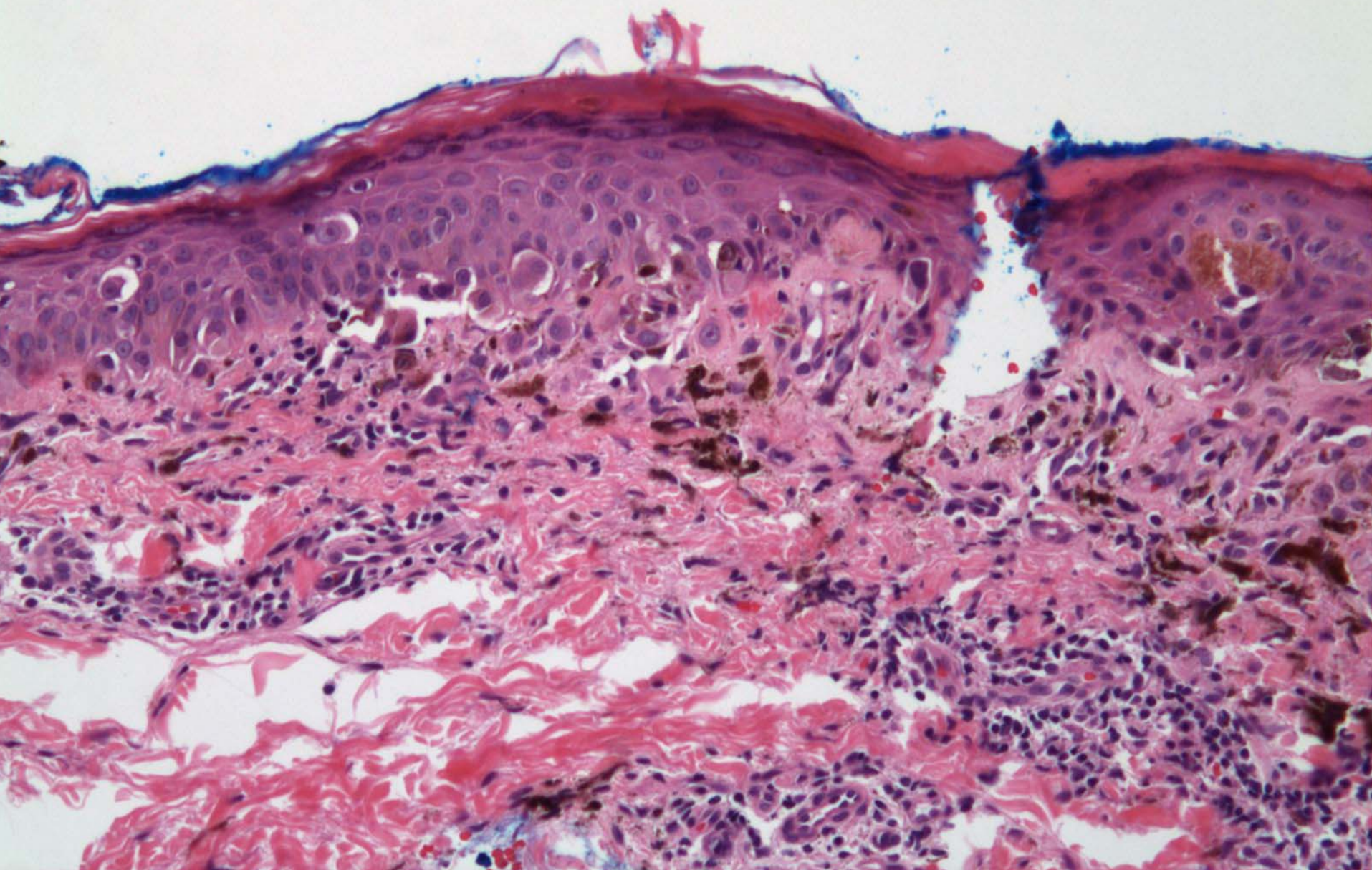










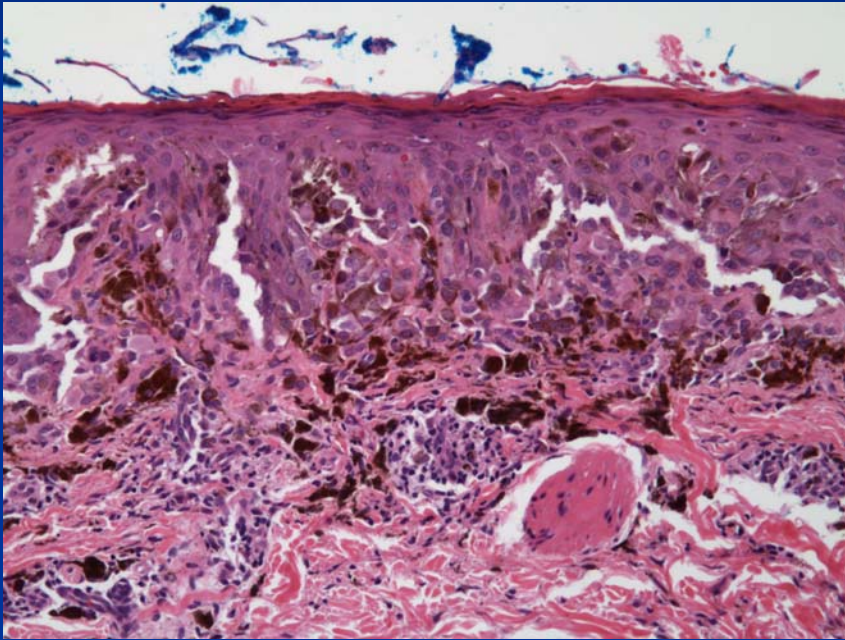




# Superficial Atypical Spitz Tumor



# Histopathology

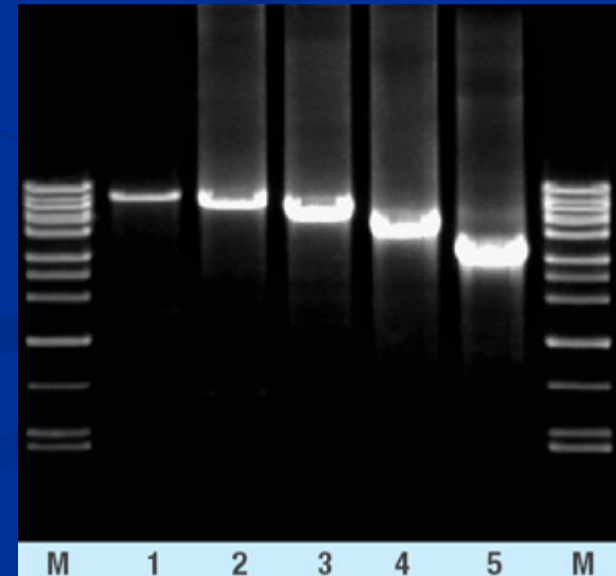


- Atypical spindled and epithelioid proliferation
- Scattered Kamino bodies
- Focal upward intraepithelial scatter
- Moderately atypical melanocytes

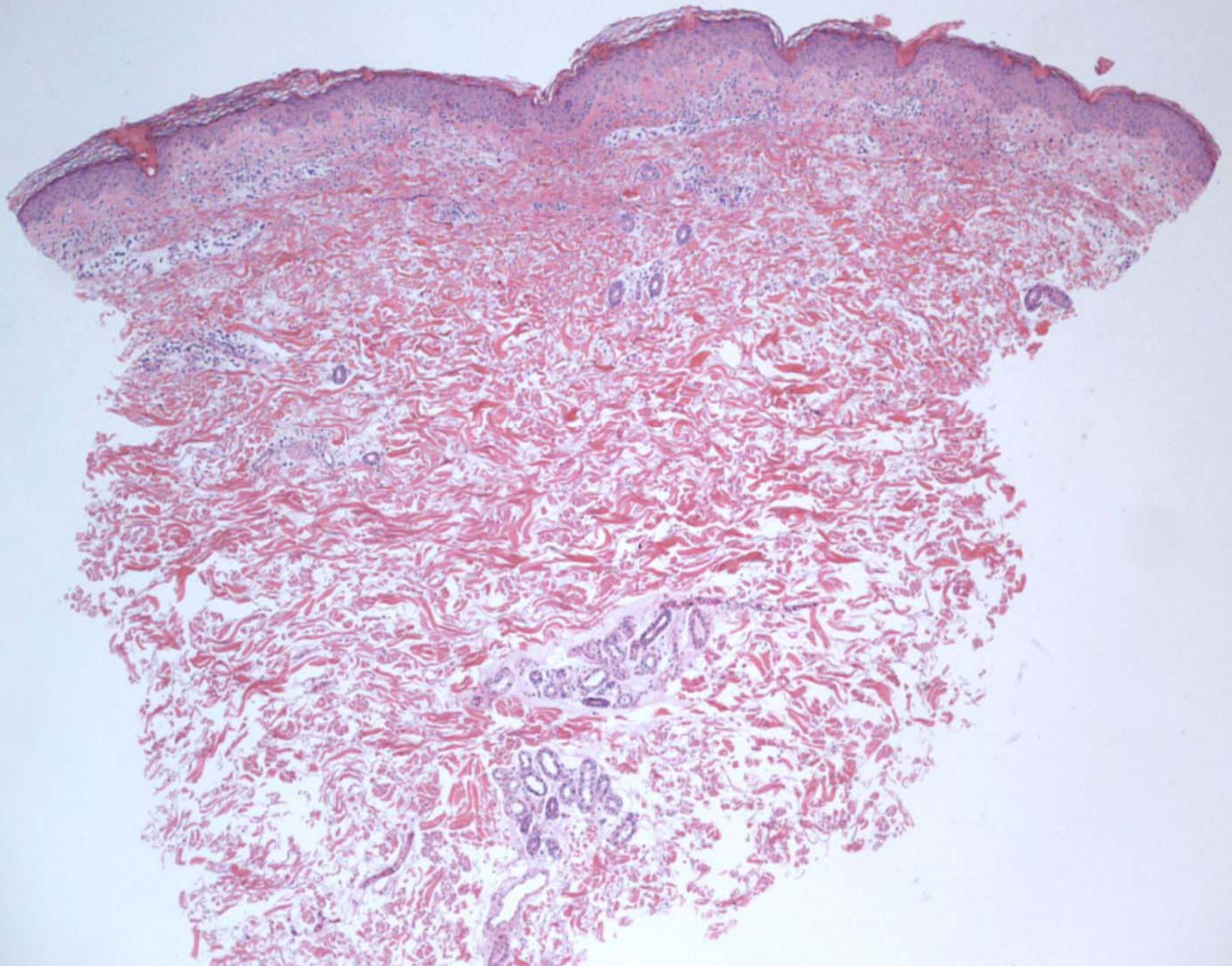




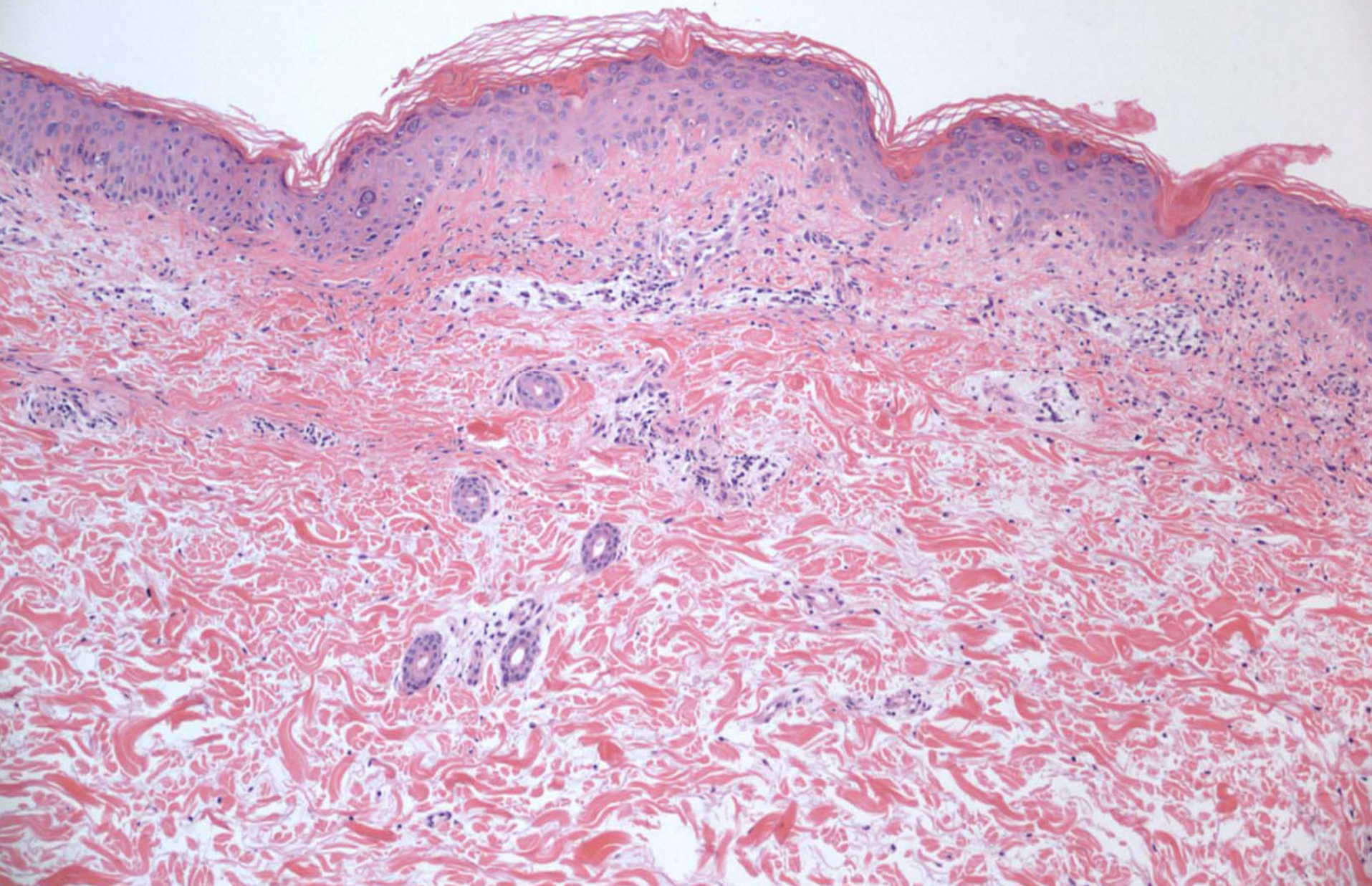
# New Tests



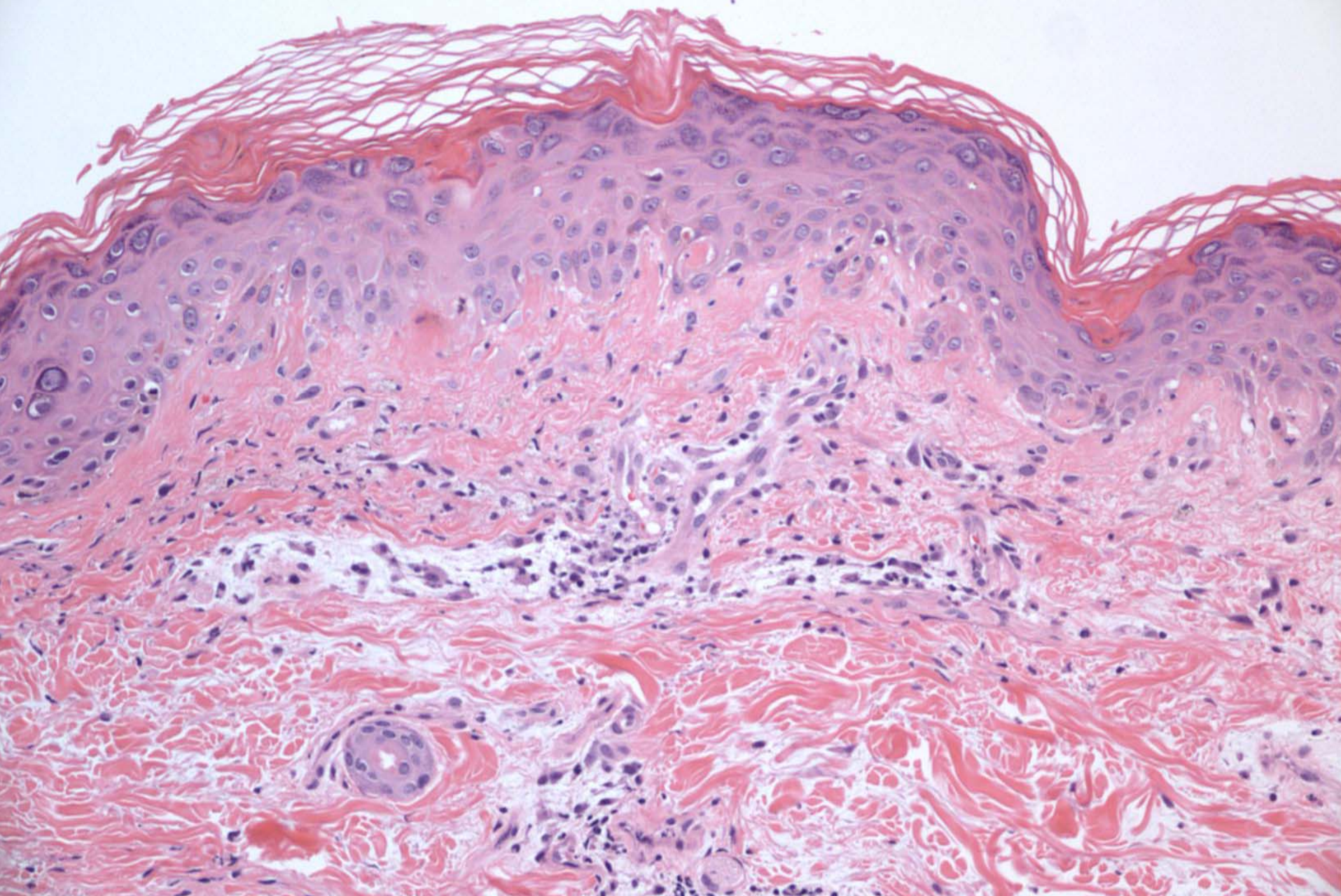




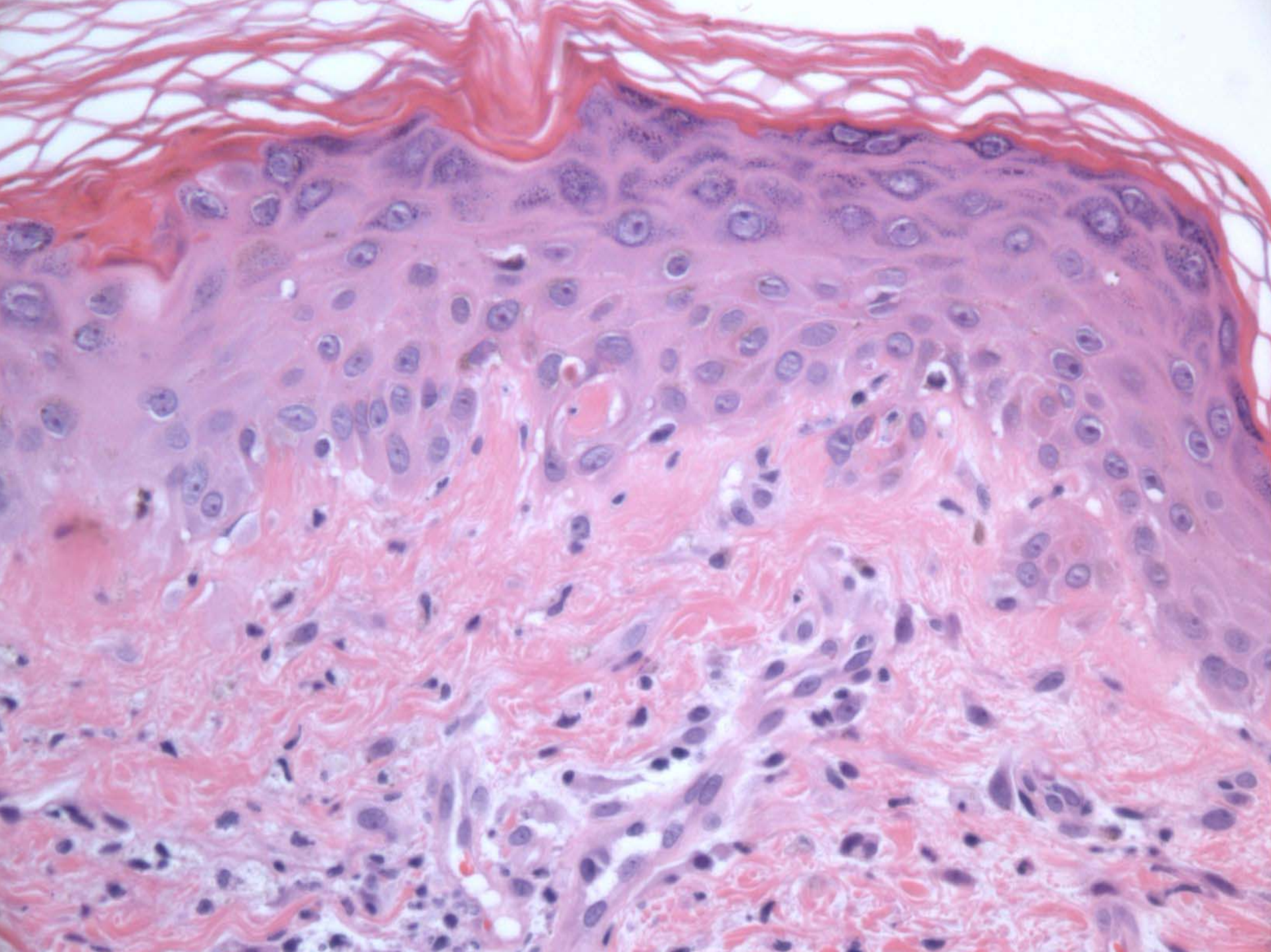




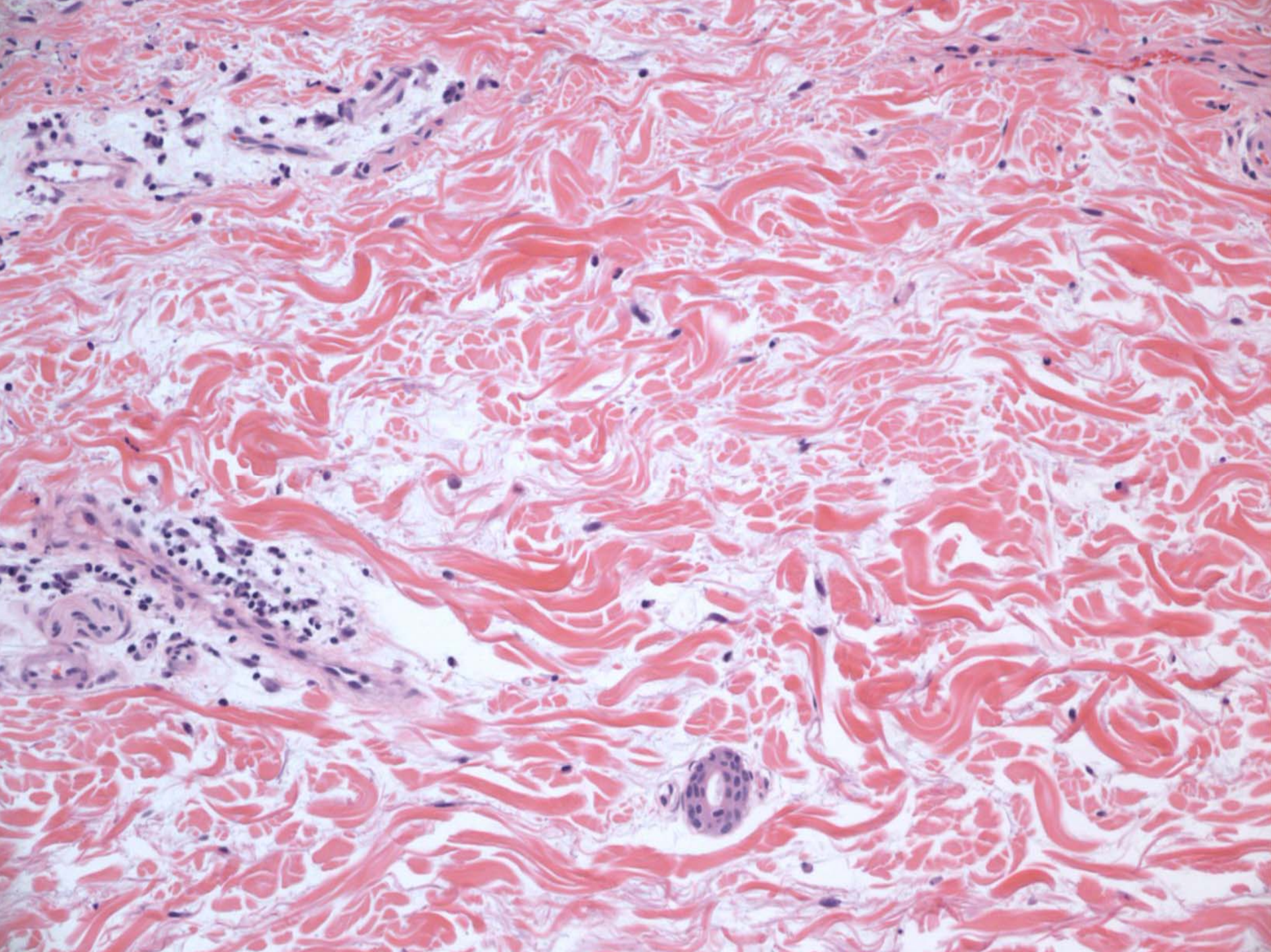




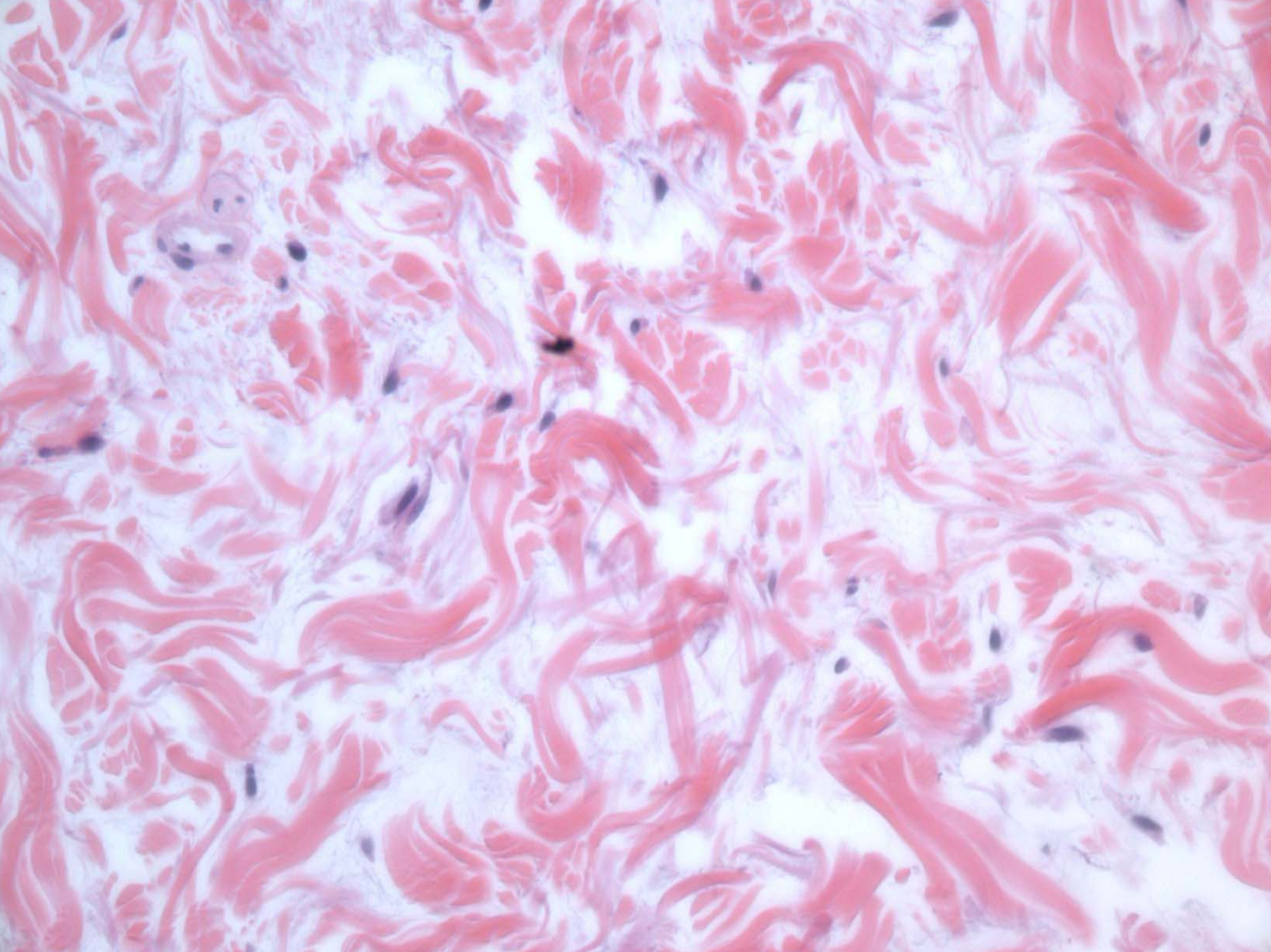






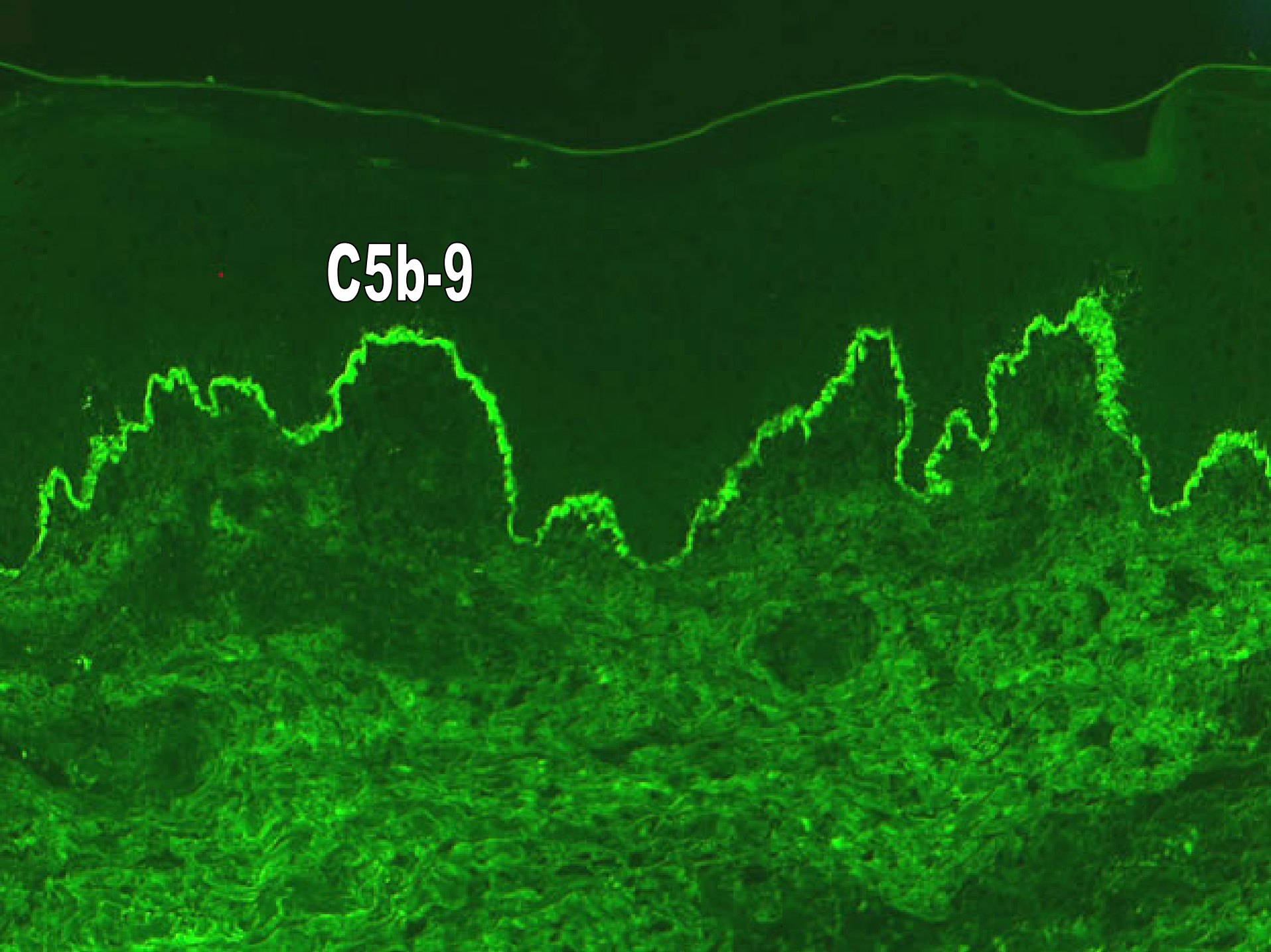






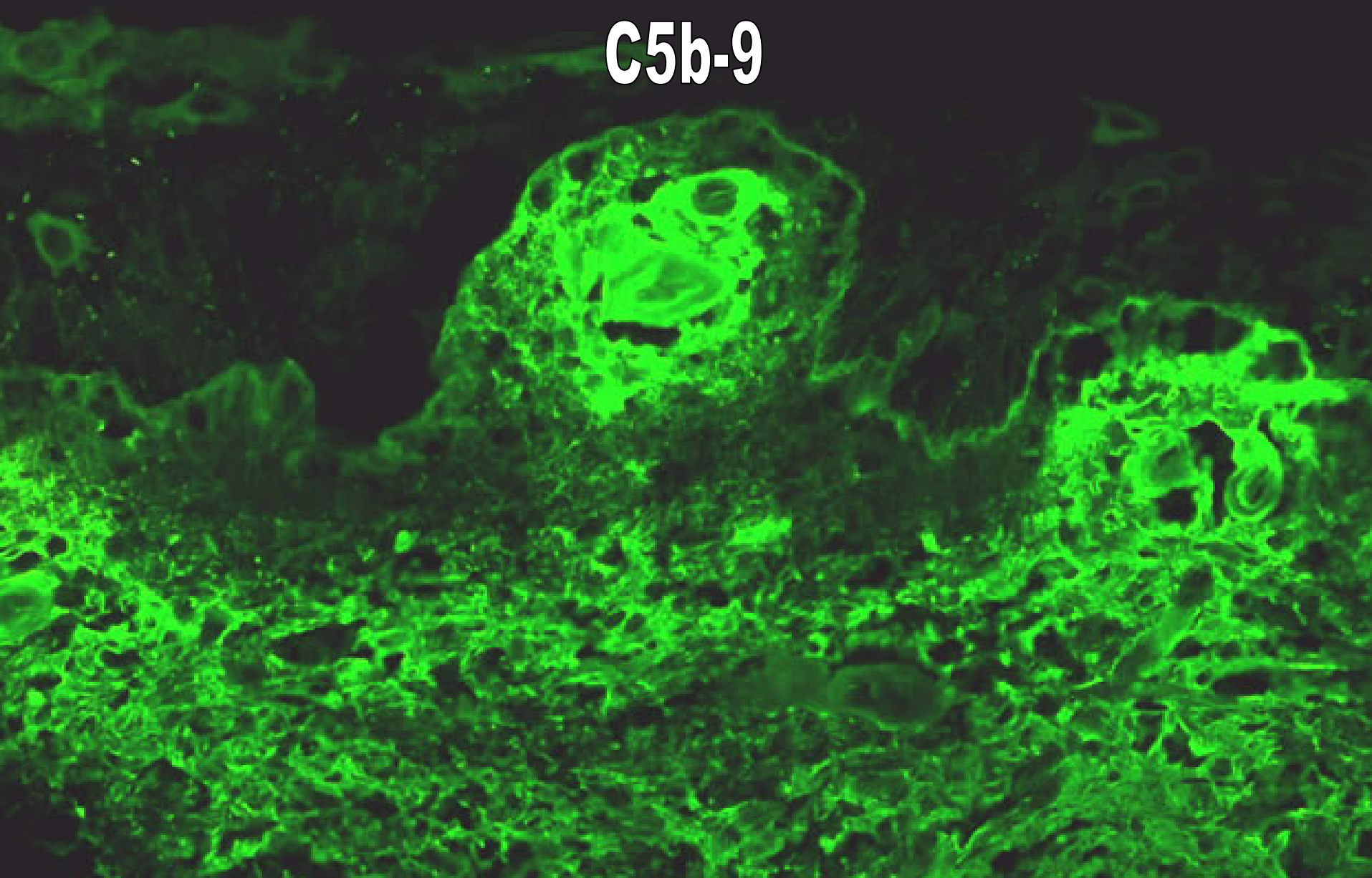


**C5b-9**





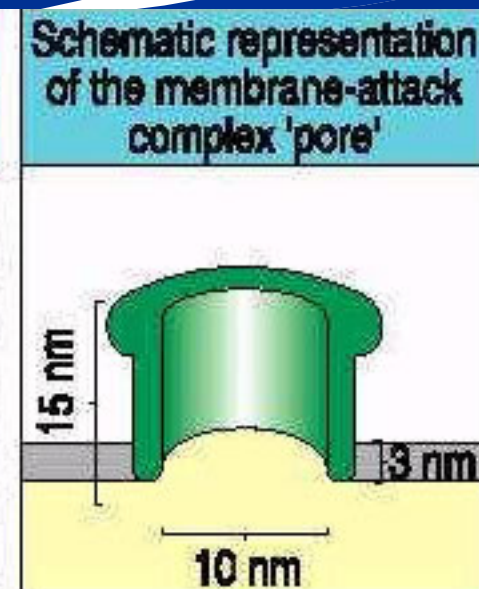
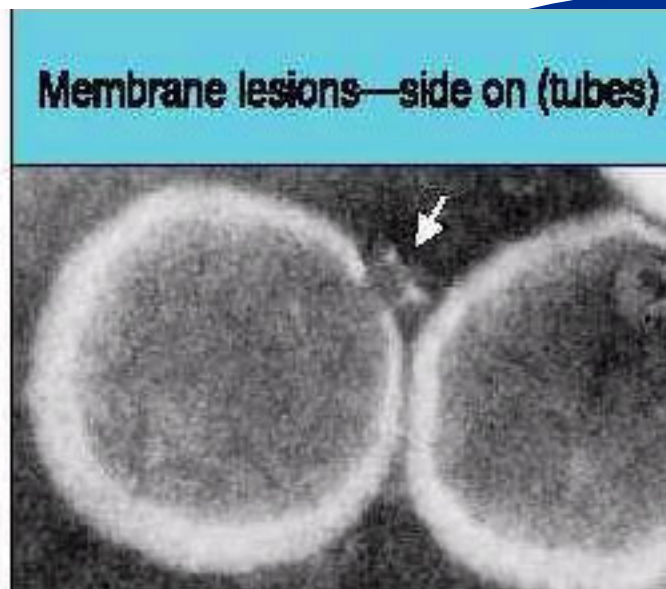
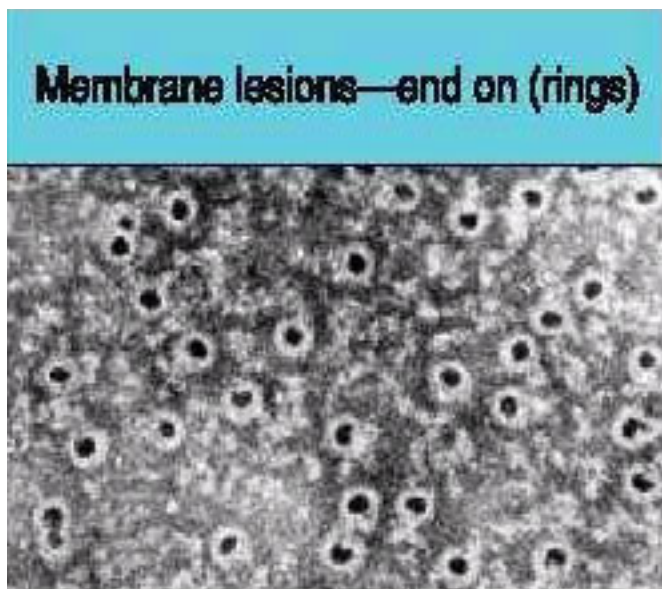
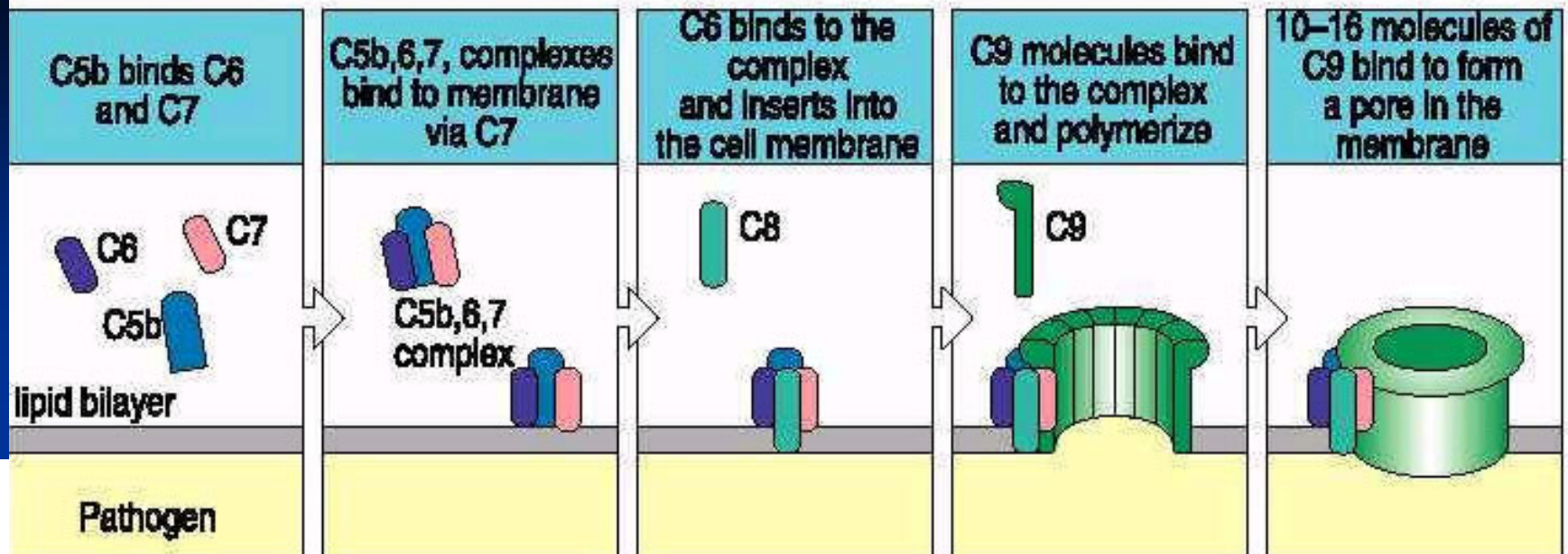
**C5b-9**





**DIF for C5b-9  
(Membrane Attack Complex)  
for  
Confirmation of Dermatomyositis**





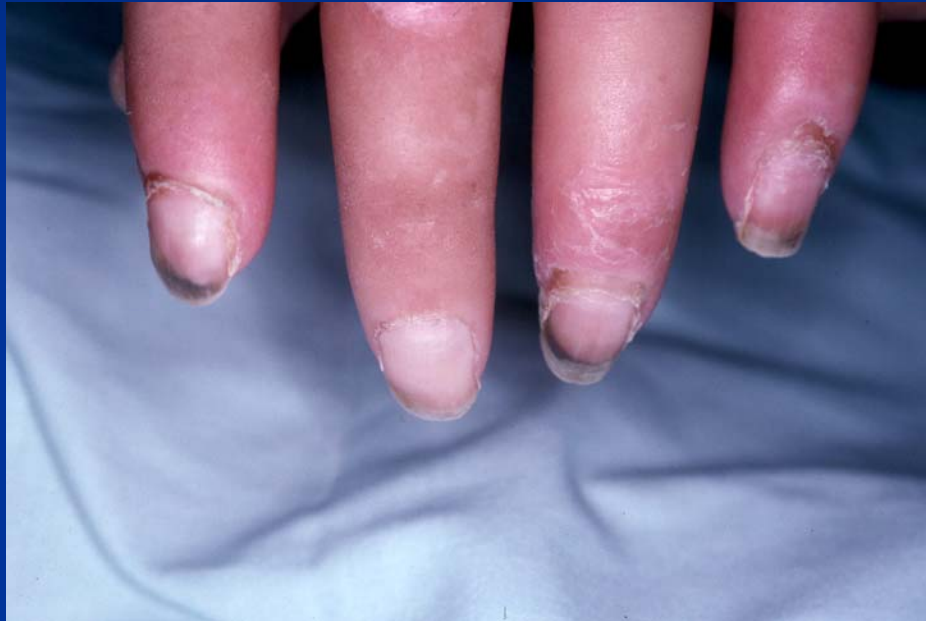

# MAC Diseases and Patterns

<b>SLE</b>	Intense granular DEJ 80%
<b>SCLE</b>	Granular DEJ 60% Granular nuclear/cytoplasmic epidermal
<b>DLE</b>	DEJ 60%
<b>MCTD</b>	Granular nuclear/cytoplasmic epidermal 100% DEJ 100%
<b>Dermatomyositis</b>	DEJ 90% Endothelial cells Dermal papillary capillaries



# Overlap



- Anti-Ro associated SLE, Dermatomyositis, and MCTD
  - Endothelial C5b-9
  - Endothelial cell necrosis and denudement
  - Reduction in vascular plexus
  - Granular and cytoplasmic decoration keratinocytes
  - Differentiate by LBT and clinical
- Non-lesional skin
  - Usually negative or very weak

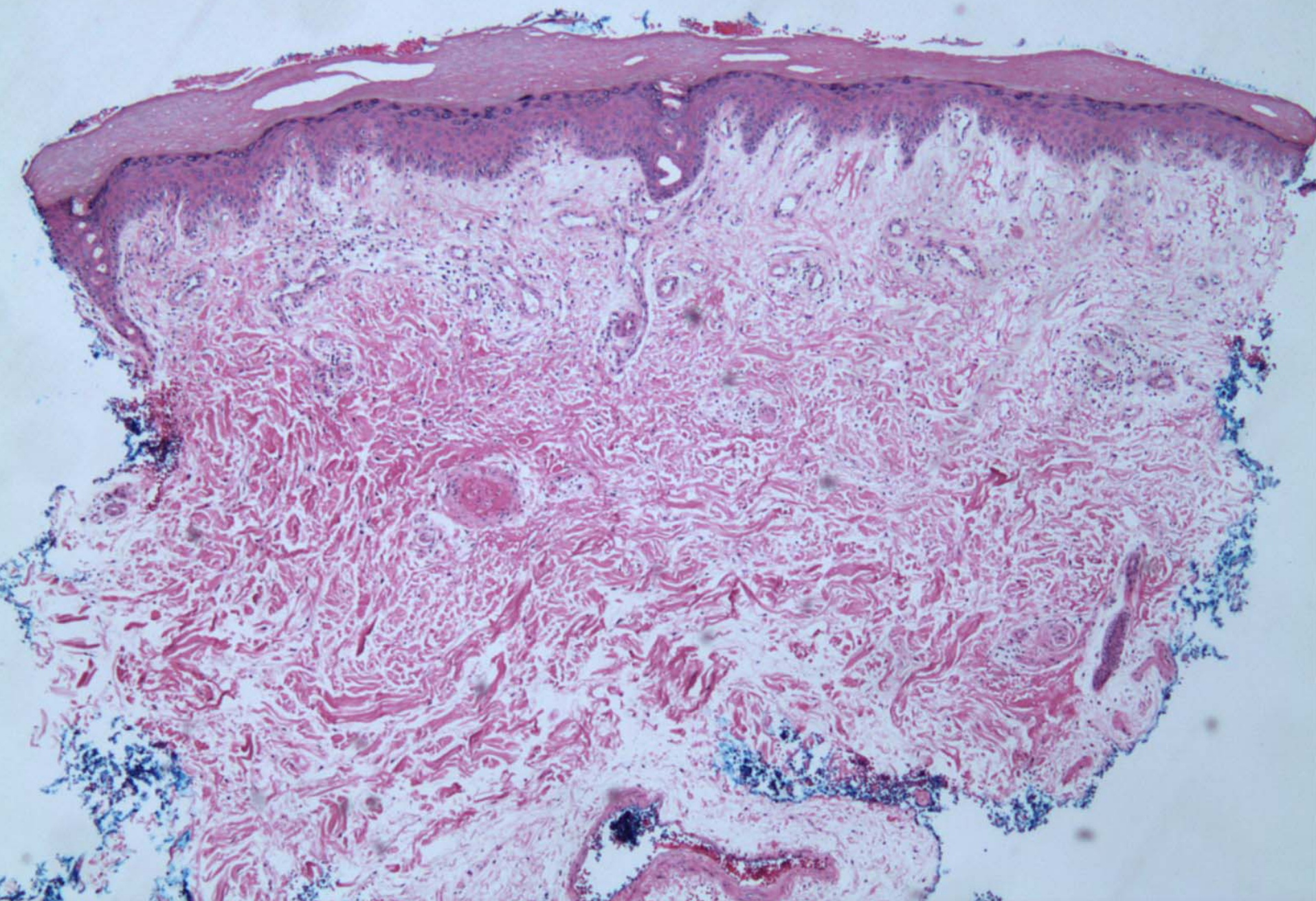




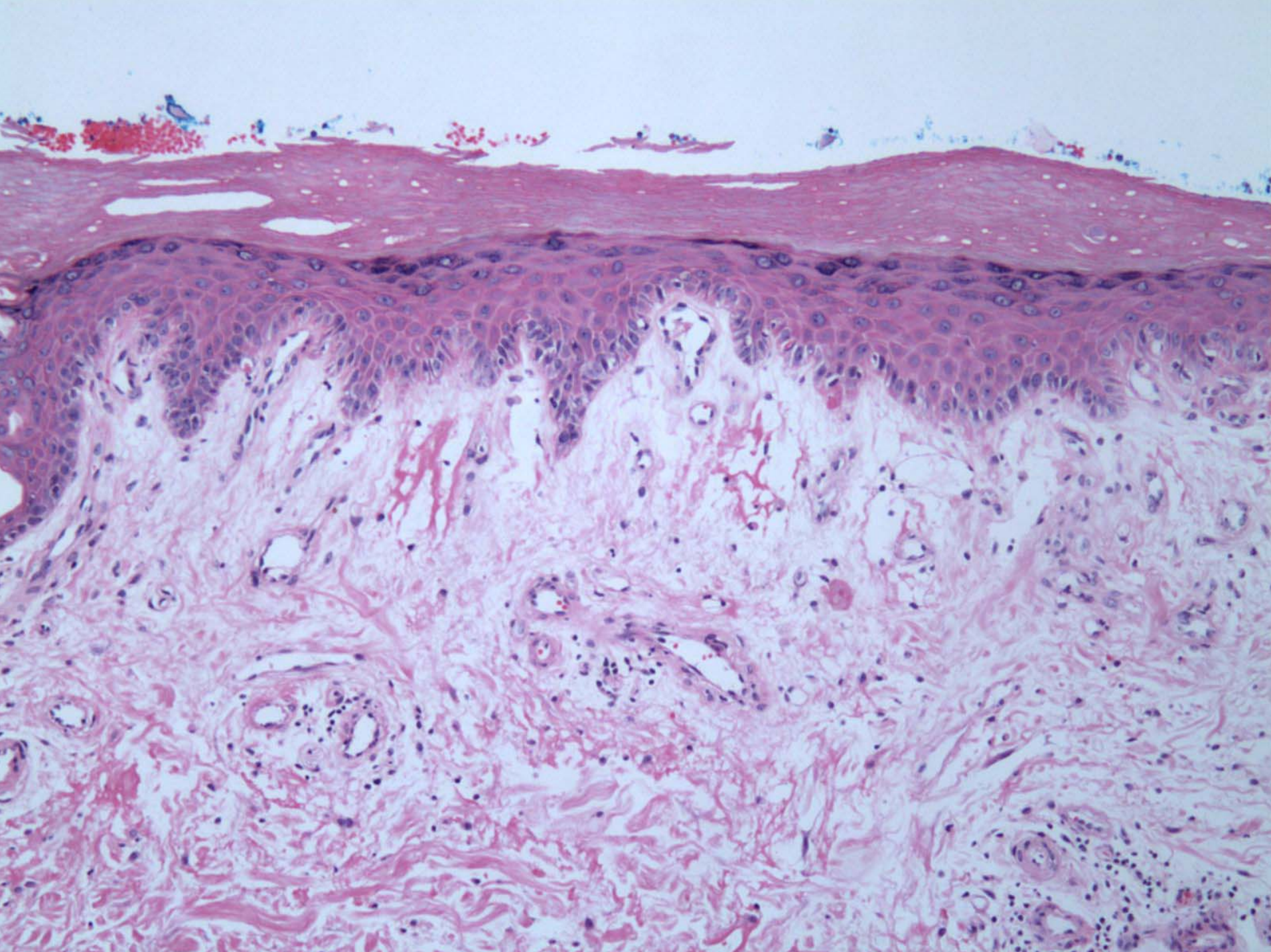
Unusual  
**ASSOCIATIONS**



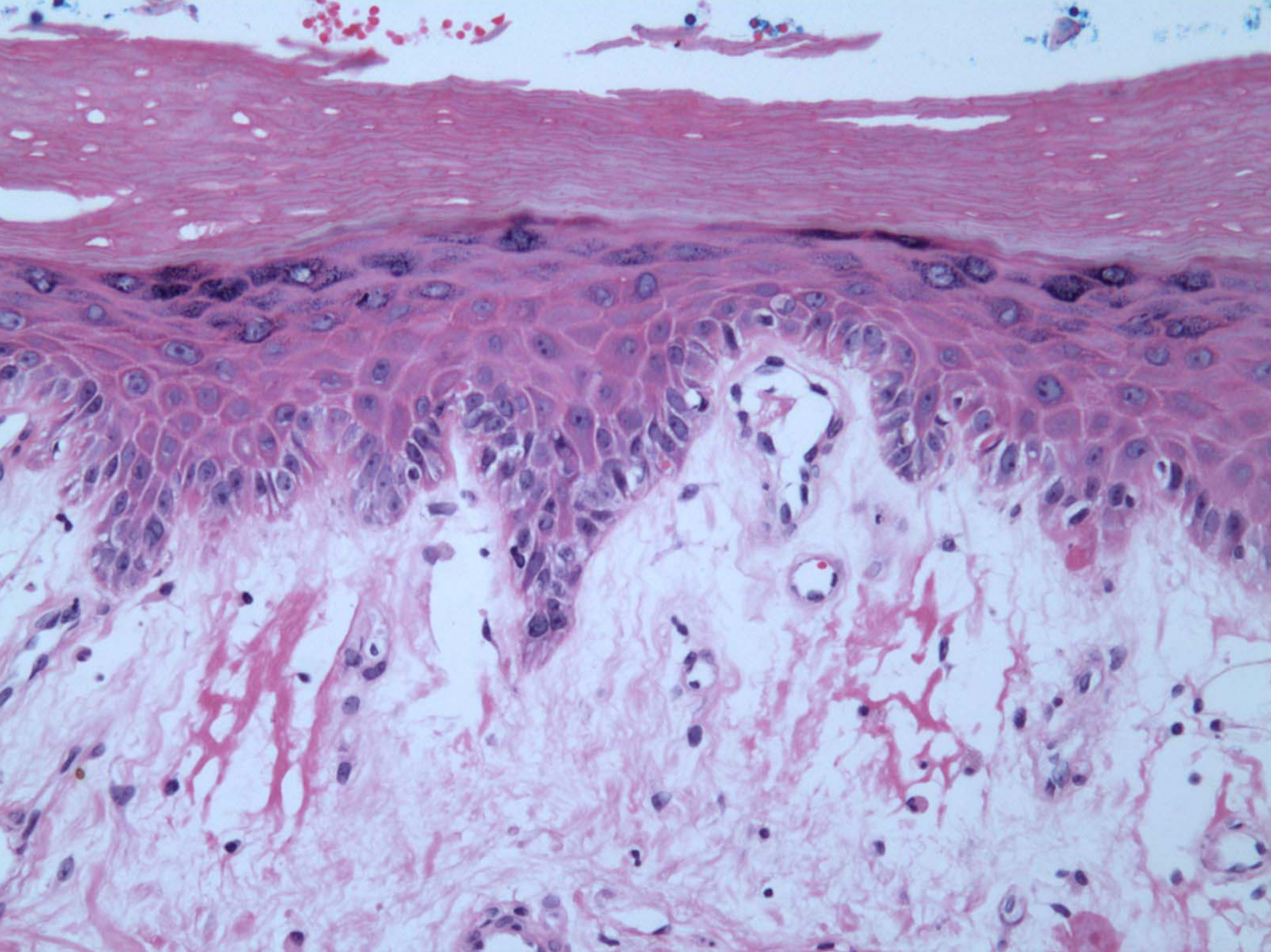




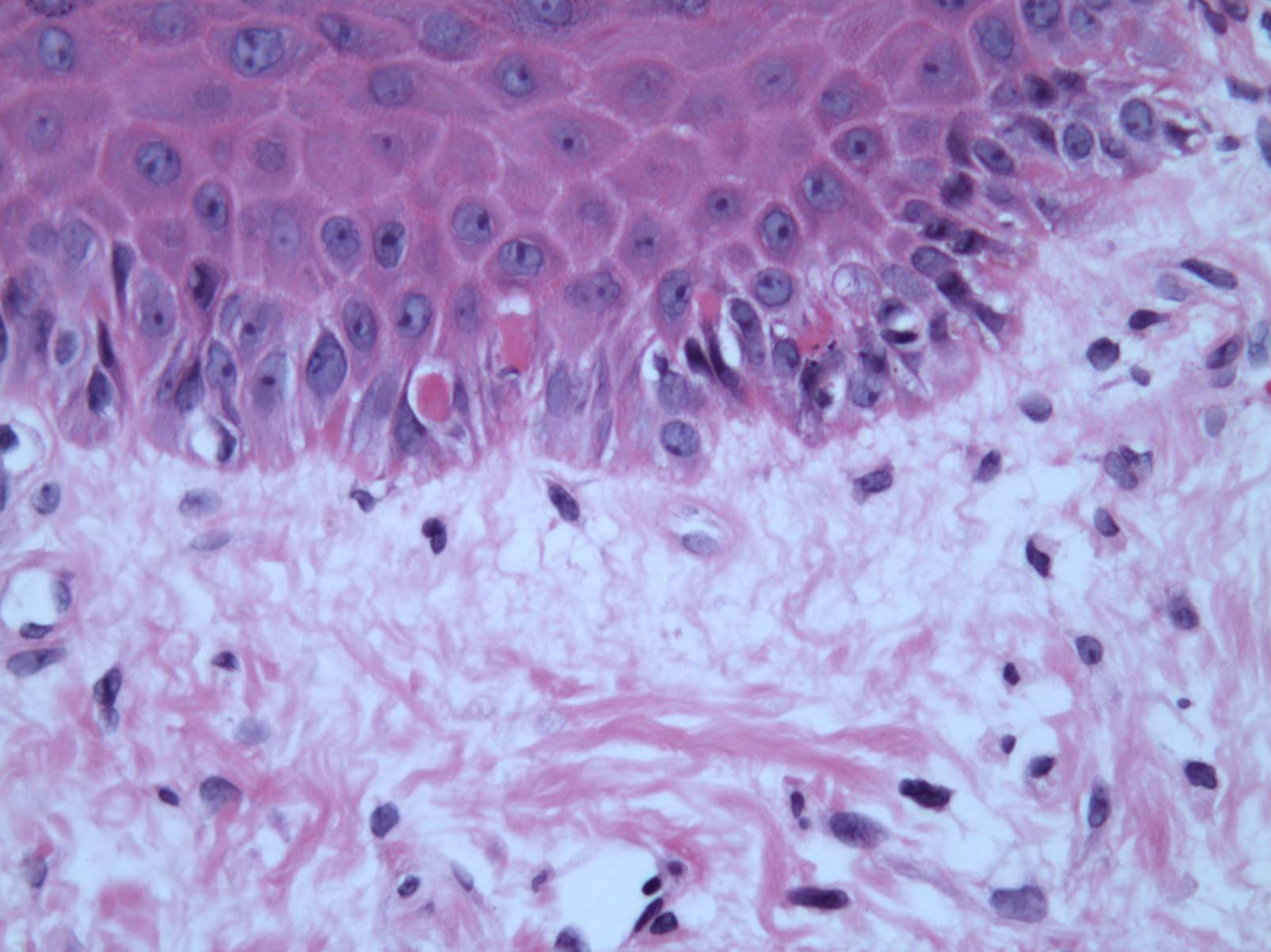




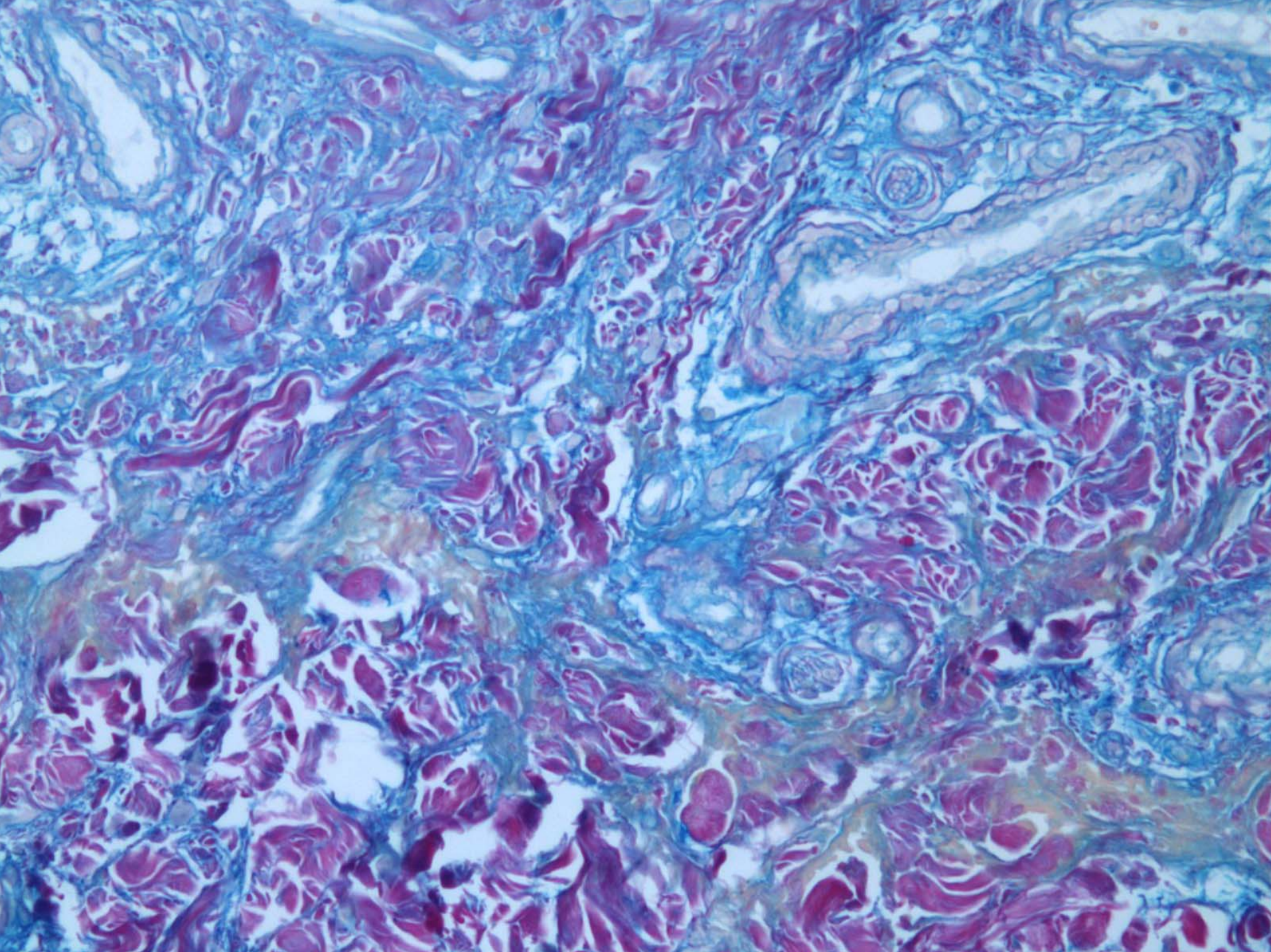




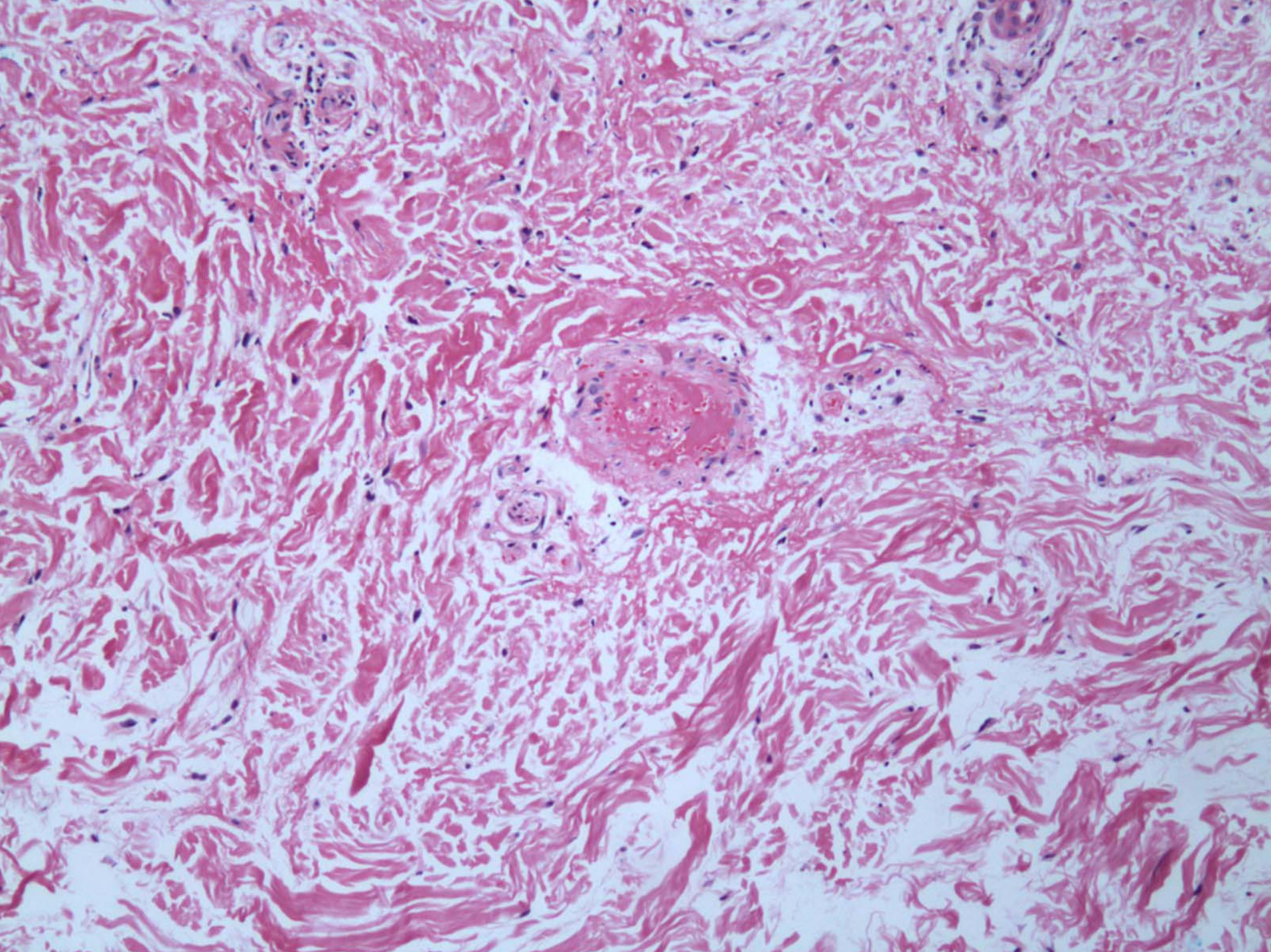




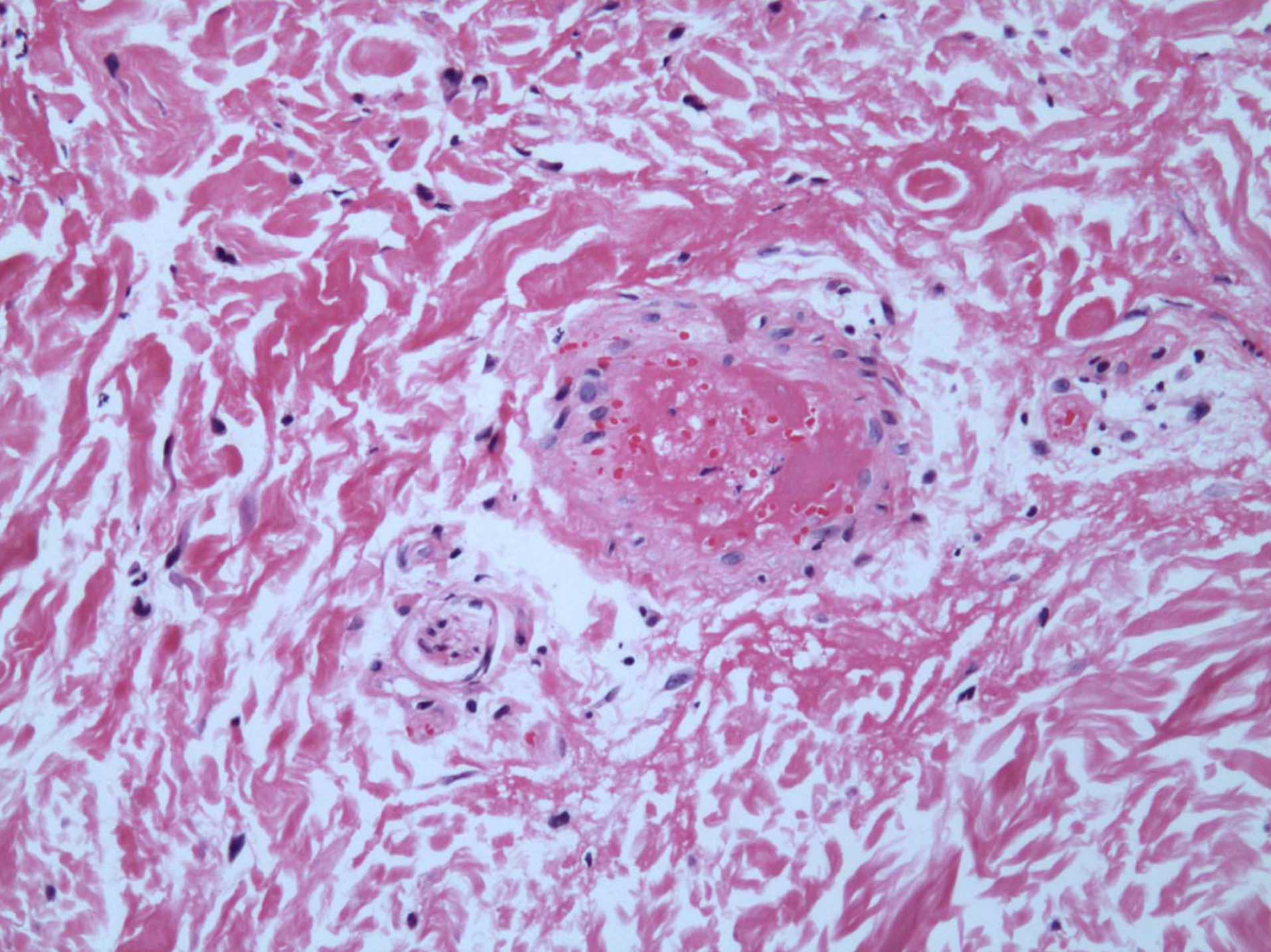




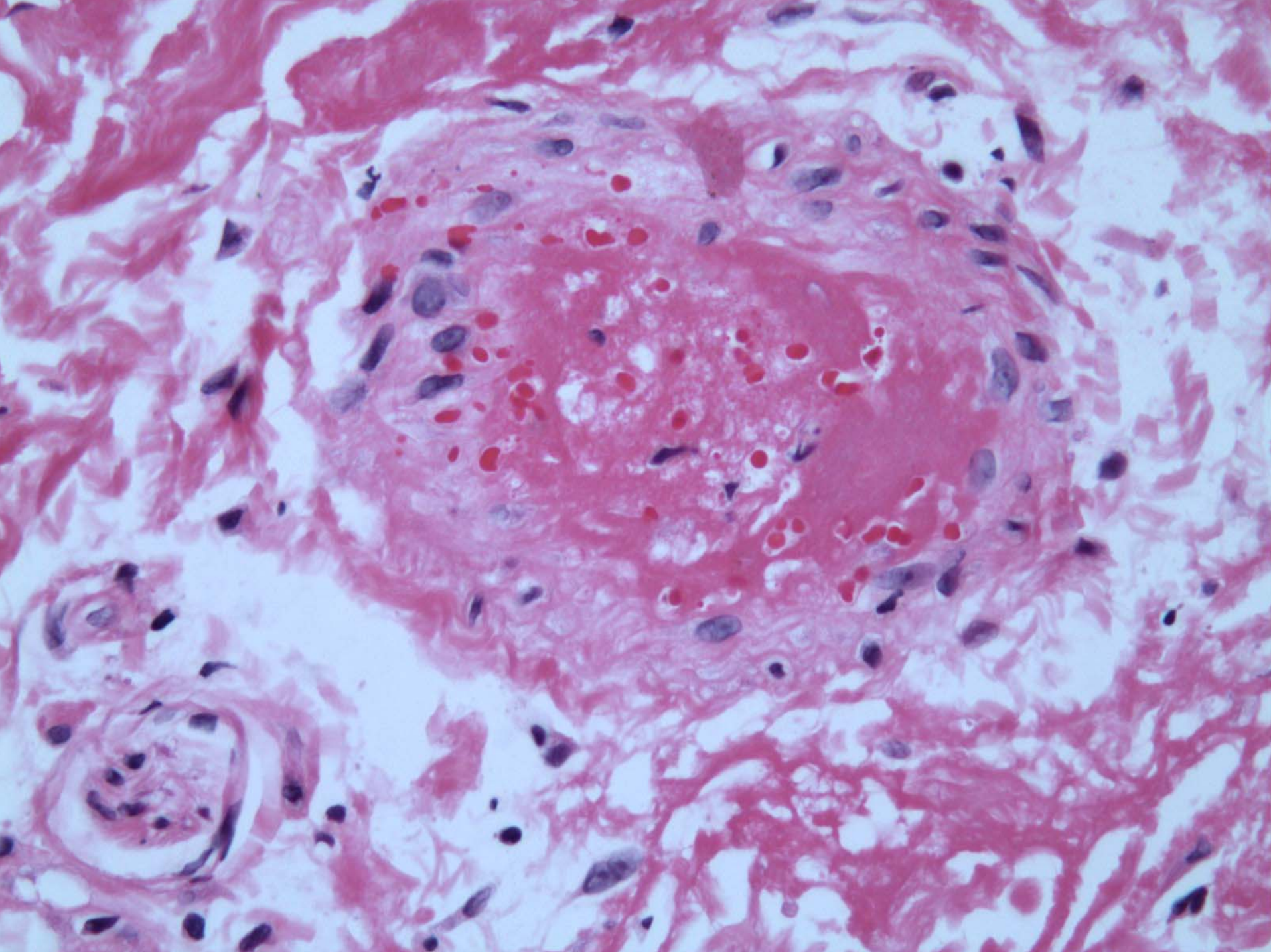










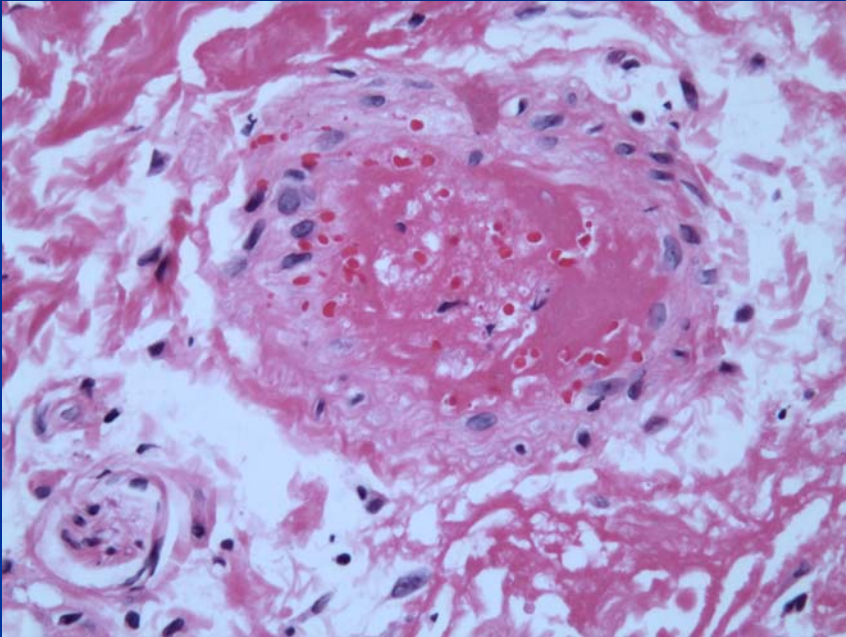




**Dermatomyositis  
associated with  
Intravascular Thrombosis**



# Points to Consider



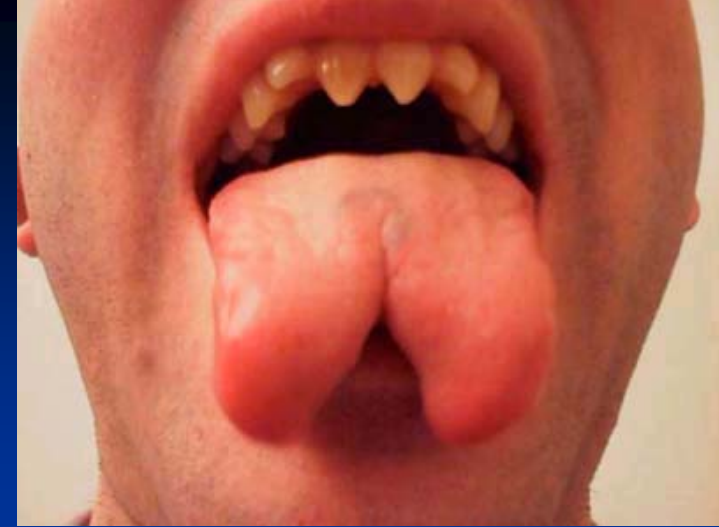- Underlying coagulopathy
- Anti-phospholipid Ab
- Protein C/Protein S Def.
- Malignancy associated dermatomyositis with hypercoagulable state?



# Dermatomyositis and Thrombosis

- **Miyaoka Y, et al.** A case of dermatomyositis complicated by thrombotic thrombocytopenic purpura. *Dermatology*. 1997;194(1):68-71.
- **Huemer C, et al.** Juvenile dermatomyositis with major thrombosis-an unusual course. *Clin Exp Rheumatol*. 1995 Nov-Dec;13(6):795
- **Sherer Y, et al.** Dermatomyositis and polymyositis associated with the antiphospholipid syndrome-a novel overlap syndrome. *Lupus*. 2000;9(1):42-6.



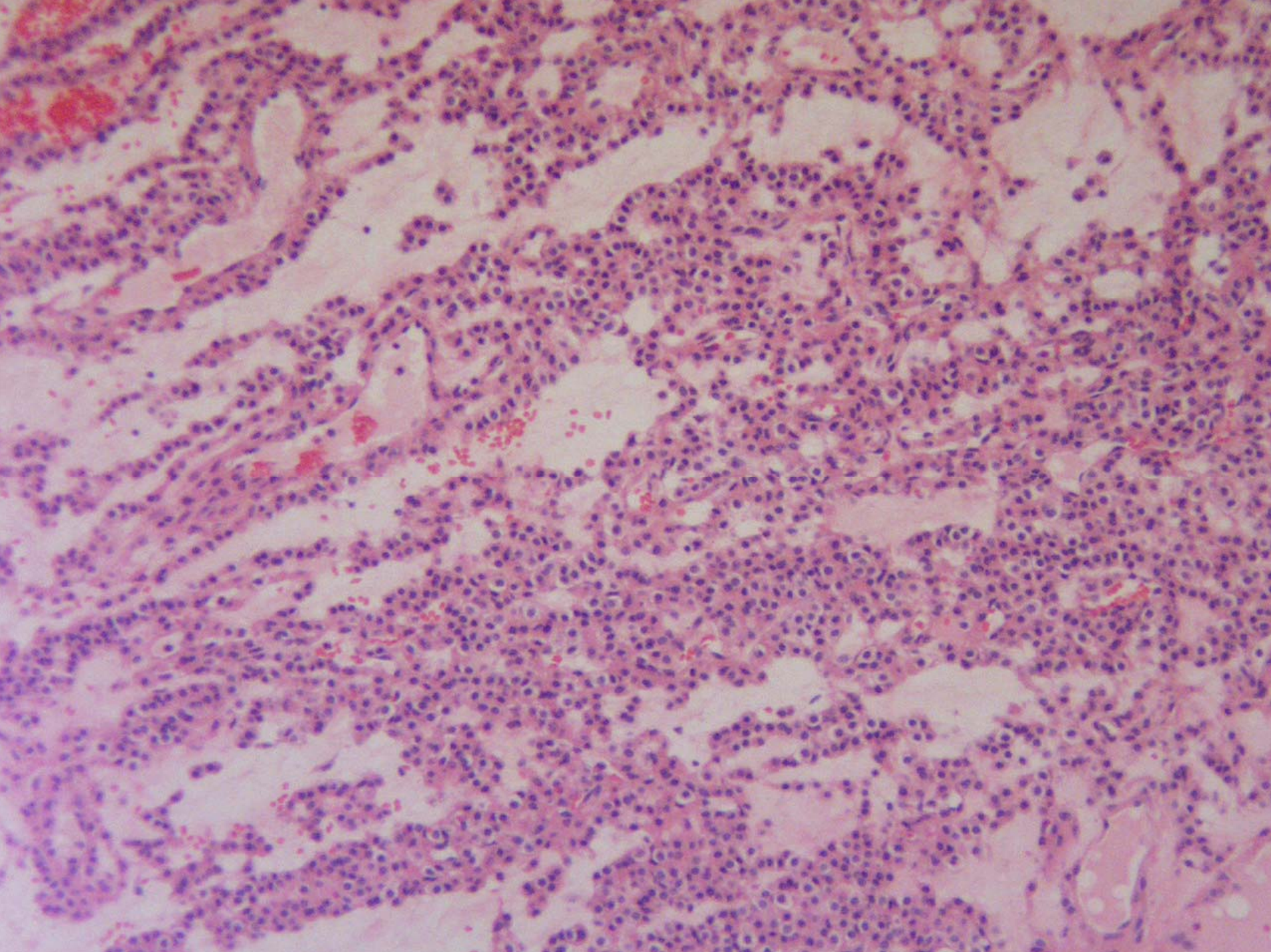


# Fascinomas

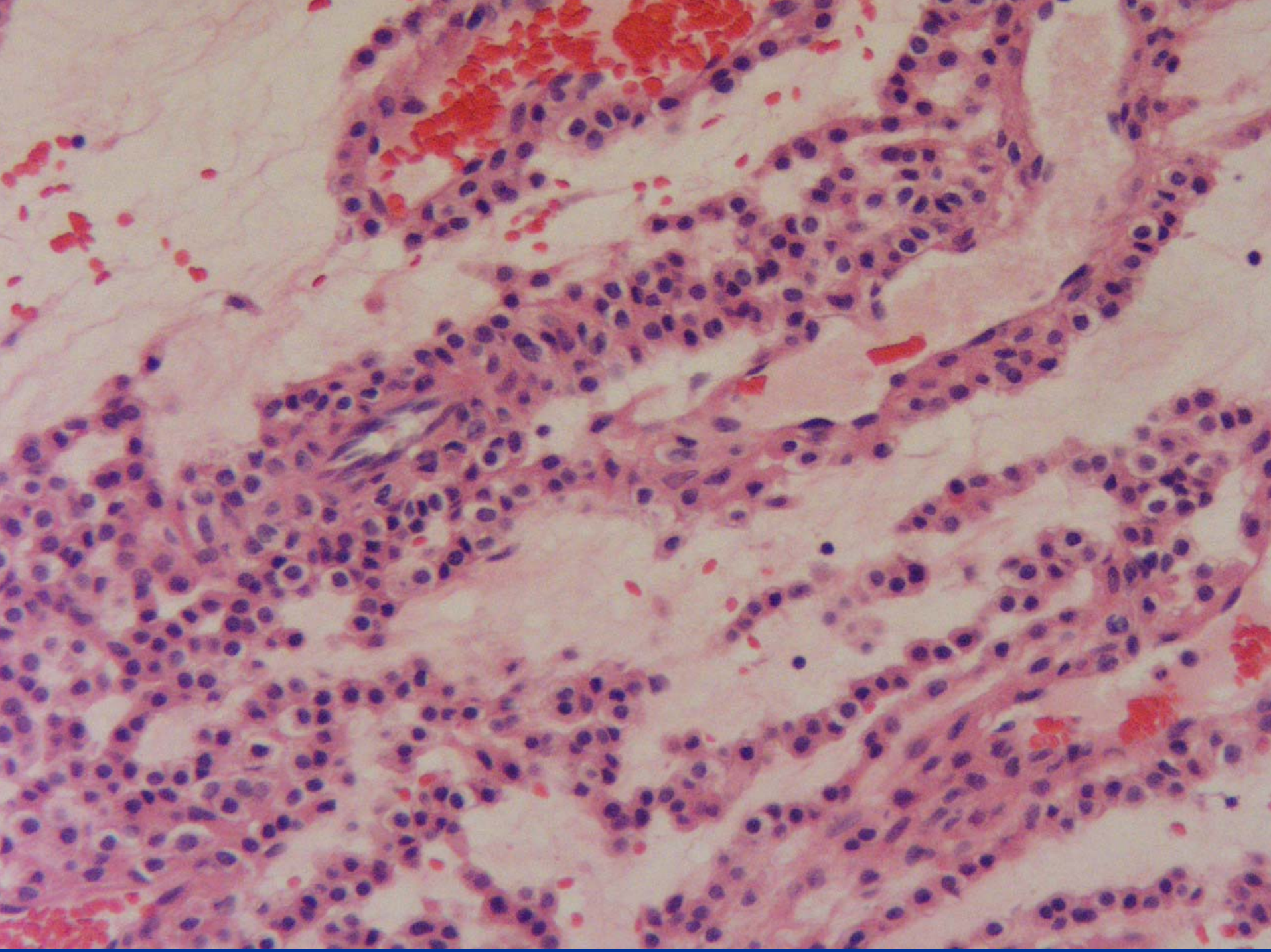


*The world of Healthy Smiles*

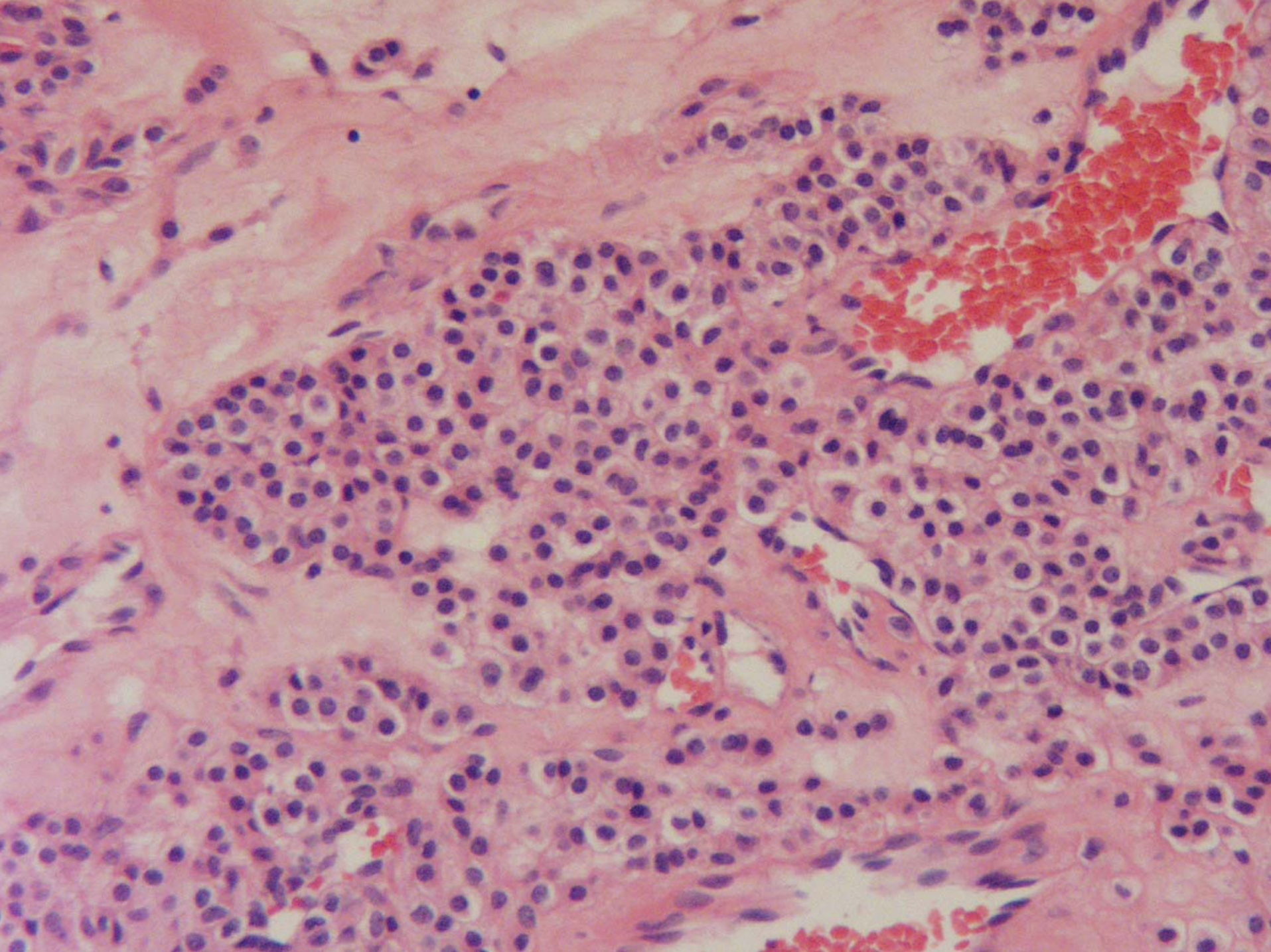




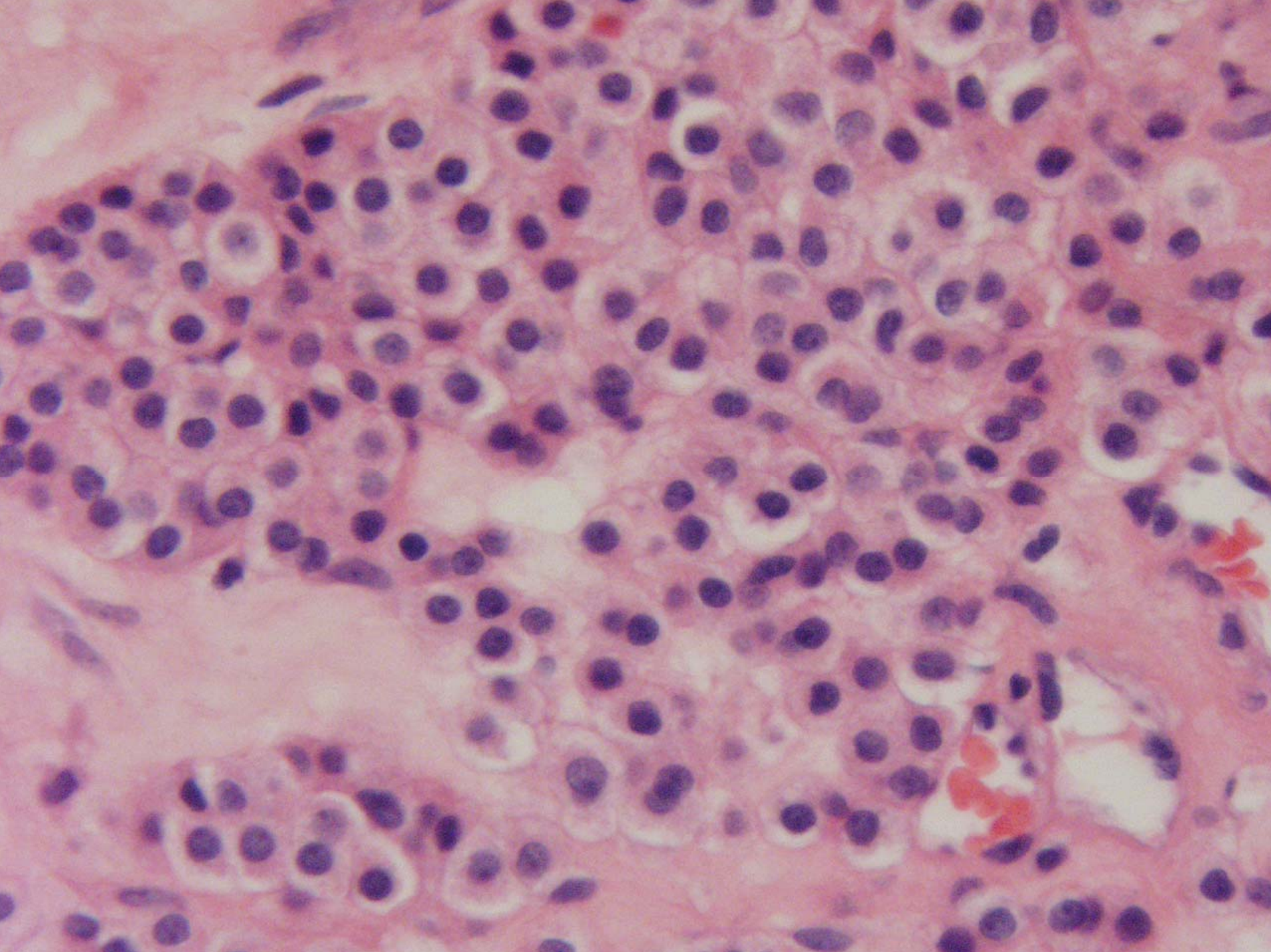




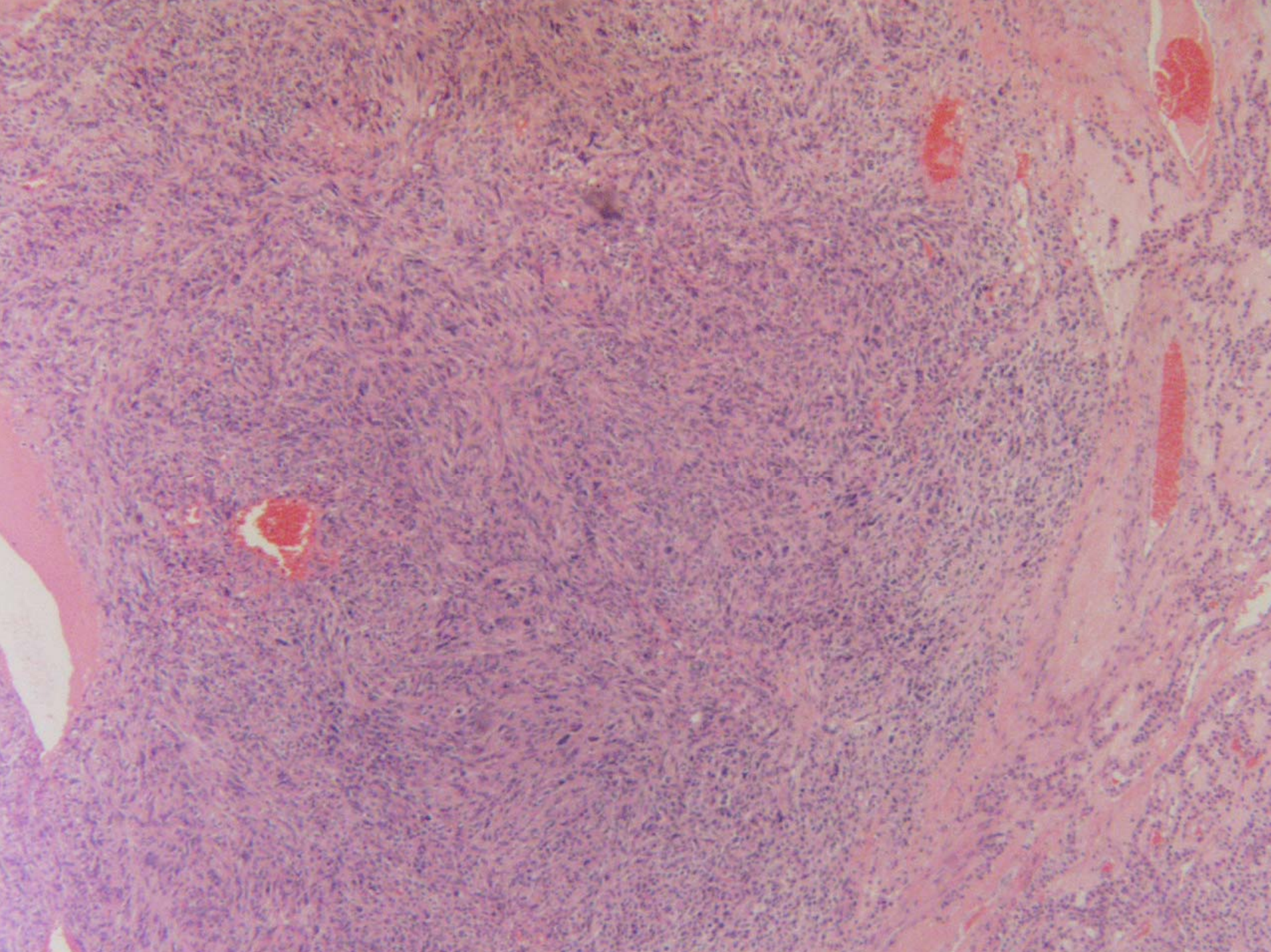




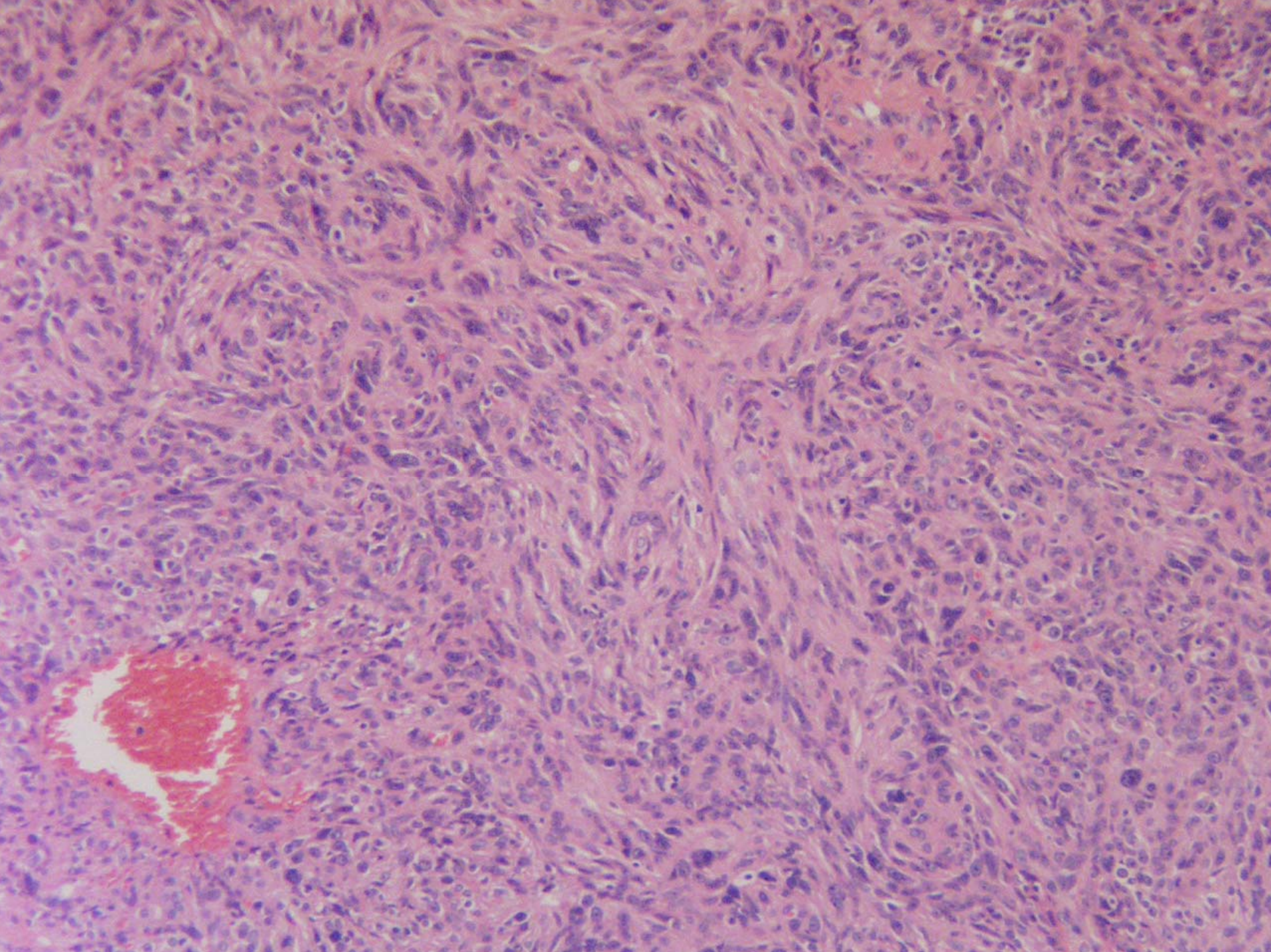




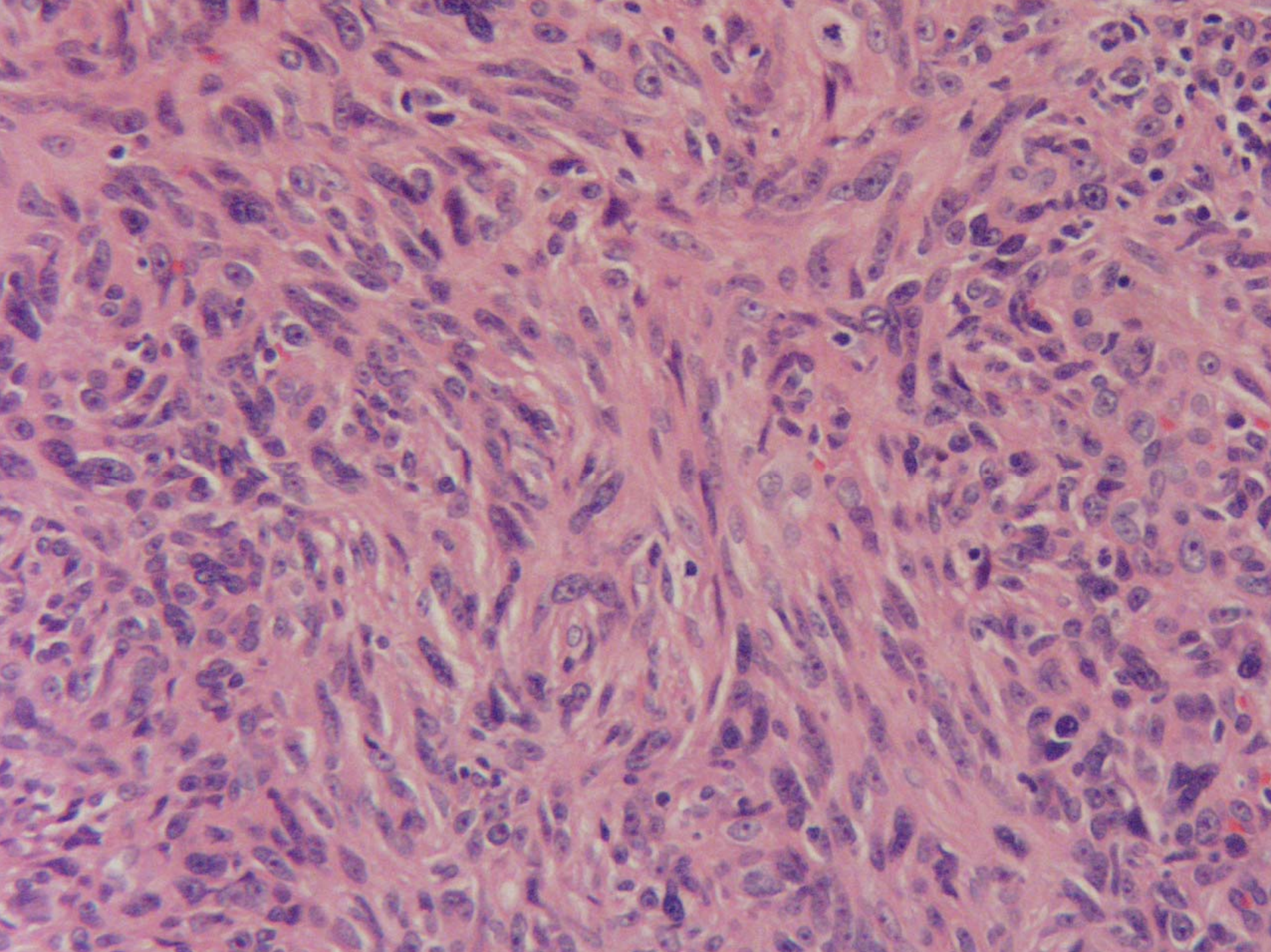




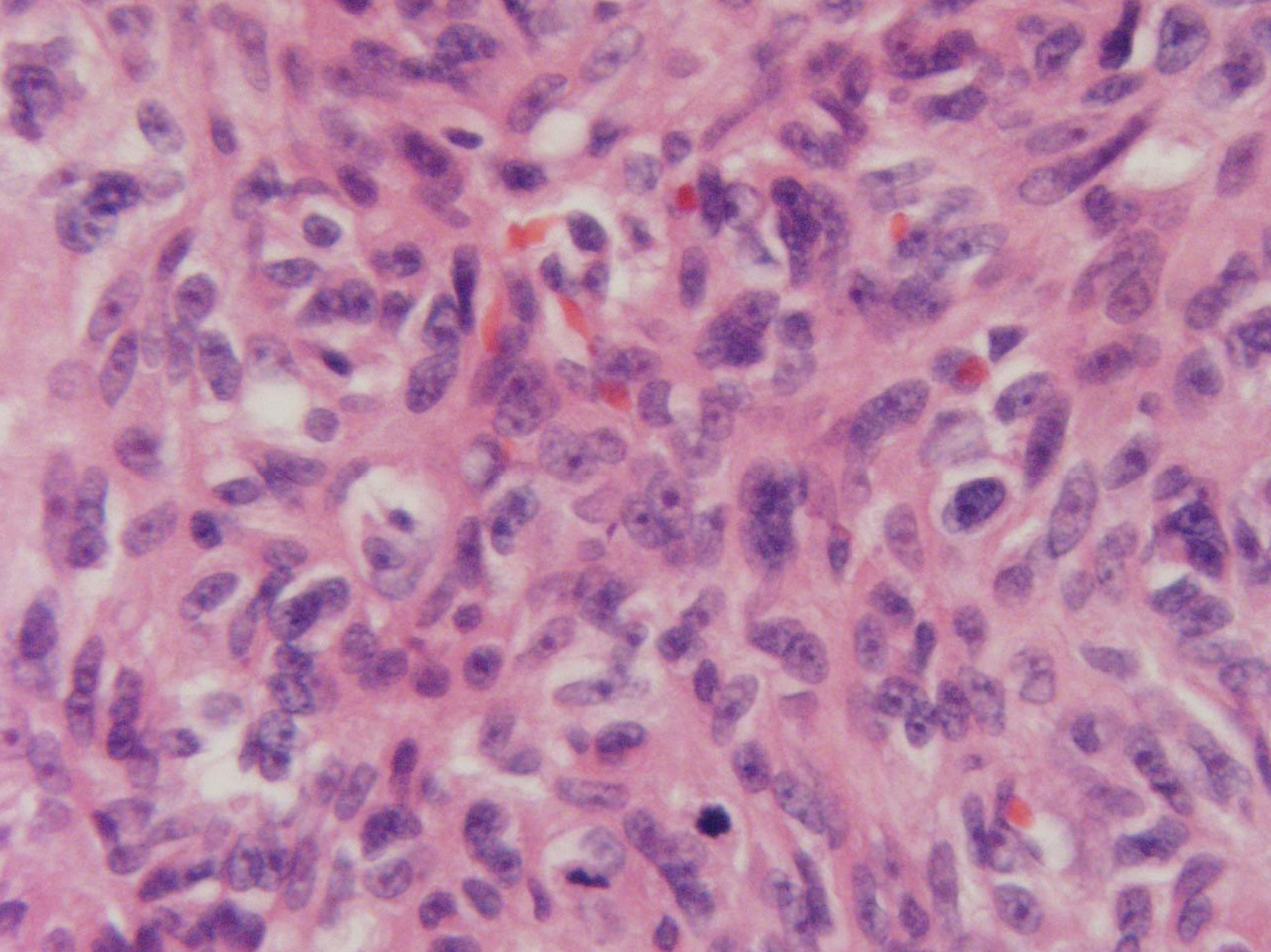




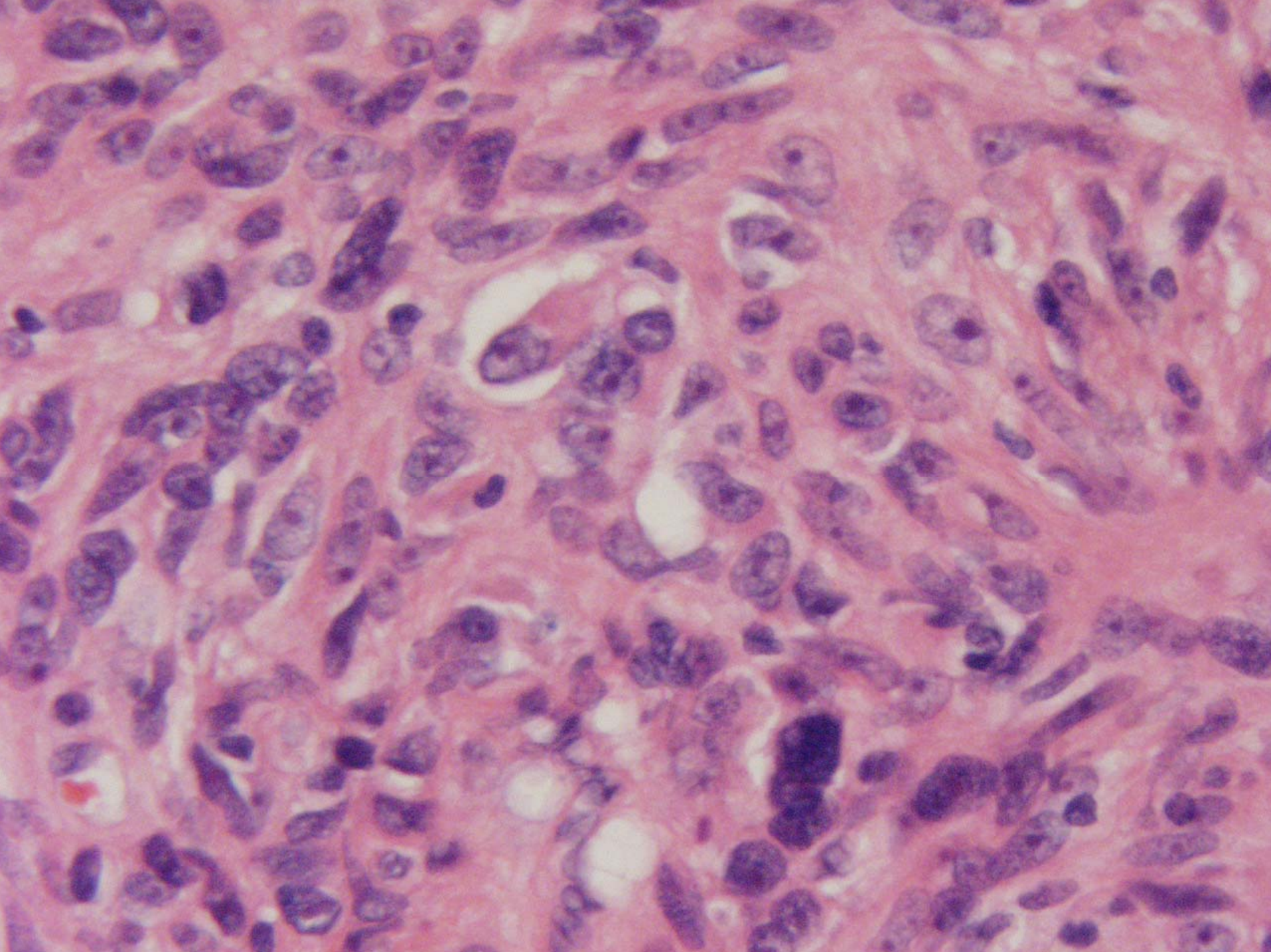










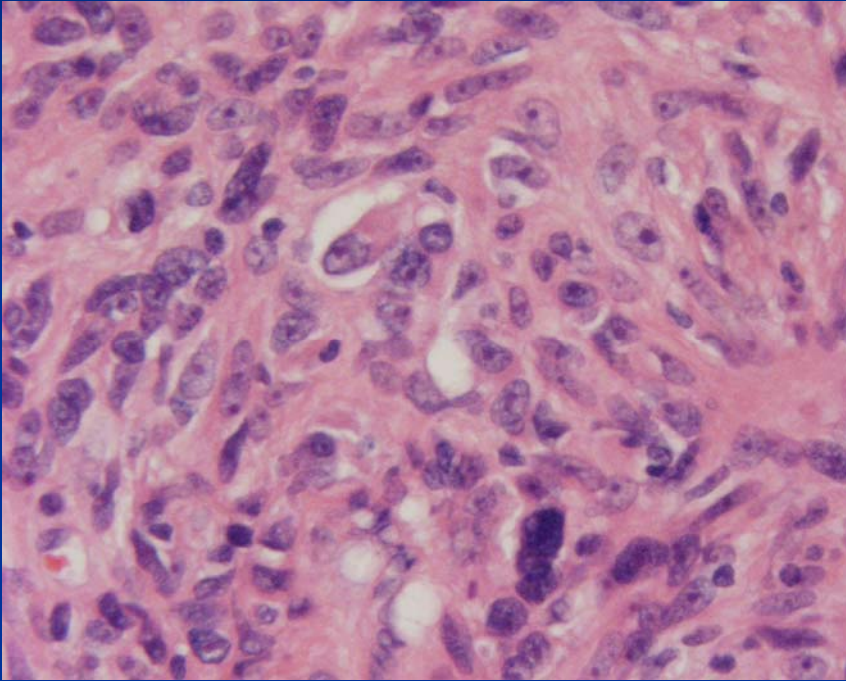




# Malignant Glomus Tumor



# Histopathology



- 50% arise with pre-existing benign glomus tumor
- Deep seated lesion
- >2cm
- Atypical mitotic figures or increased >2 50 hpf



